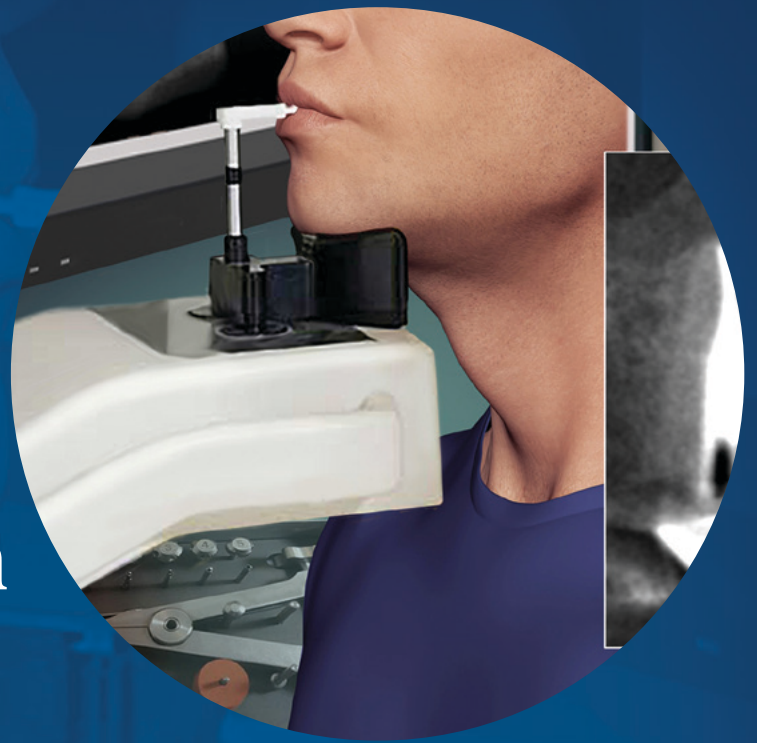

Nonsurgical Retreatment: Clinical Decision Making

Spring 2017



ENDODONTICS: Colleagues for Excellence

Published for the dental professional community by the



american association of
endodontists

www.aae.org/colleagues

Millions of teeth with disease of the pulp and periradicular tissues are saved every year through endodontic treatment. Despite the high clinical success rates of nonsurgical root canal treatment, there are times when an endodontically treated tooth may exhibit post-treatment disease requiring further intervention.

Post-treatment endodontic disease has four possible etiologies: microorganisms that are retained or reintroduced into the canal system, microorganisms that survive in the apical tissues outside the canal system, foreign body reactions in the apical tissues, and the presence of true periapical cysts (1, 2). Treatment for intracanal microorganisms includes both surgical and nonsurgical options, but the other three etiologies only can be treated surgically. Because it is often difficult to determine the causes of post-treatment endodontic disease, a thoughtful, evidence-based approach to treatment planning is necessary.

Impact of CBCT on Treatment Planning

Treatment planning for diseased teeth is complex. A thorough dental history, clinical testing and radiographic examination are necessary to make an accurate diagnosis prior to initiating treatment. The recent introduction of three-dimensional imaging has had a significant impact on endodontic treatment planning. Limited field of view (FOV) cone beam computed tomography (CBCT) is the imaging modality of choice for teeth with post-treatment disease. The Joint Position Statement of the American Association of Endodontists and the American Academy of Oral and Maxillofacial Radiology (3) states that limited FOV CBCT should be the imaging modality of choice when evaluating the nonhealing of previous endodontic treatment, as well as for nonsurgical retreatment to assess treatment complications or deficiencies that may have occurred during the previous endodontic therapy. When compared to other types of CBCT devices with larger FOVs, the smaller FOV generally provides higher resolution with less radiation exposure. Limited FOV CBCT enables the clinician to consider selective root retreatment, addressing only the roots with radiographic evidence of disease (4), because of its increased sensitivity in detecting roots with a periapical low density area when compared to 2-D radiographs (5). Perhaps the most compelling evidence supporting the diagnostic value of CBCT in endodontics came from three recent studies showing that when CBCT data was added to otherwise complete diagnostic information, the subsequent treatment plan was changed in 35 to 62% of the cases (6-8).

Limited FOV CBCT is useful in identifying untreated canals and root perforations, assessing complex anatomy such as fins or fused roots, evaluating instrumentation and obturation quality, and visualizing bone loss patterns that are consistent with apical periodontitis, marginal periodontitis, furcation involvement, or root fractures (Figure 1) (9). Many times, situations can be discovered that would preclude successful endodontic retreatment so that clinicians and their patients can avoid the frustration of performing treatments that have a low chance of success (Figure 2). After diagnosis, treatment options must be effectively communicated to the patient so that they can make an informed decision with the clinician.

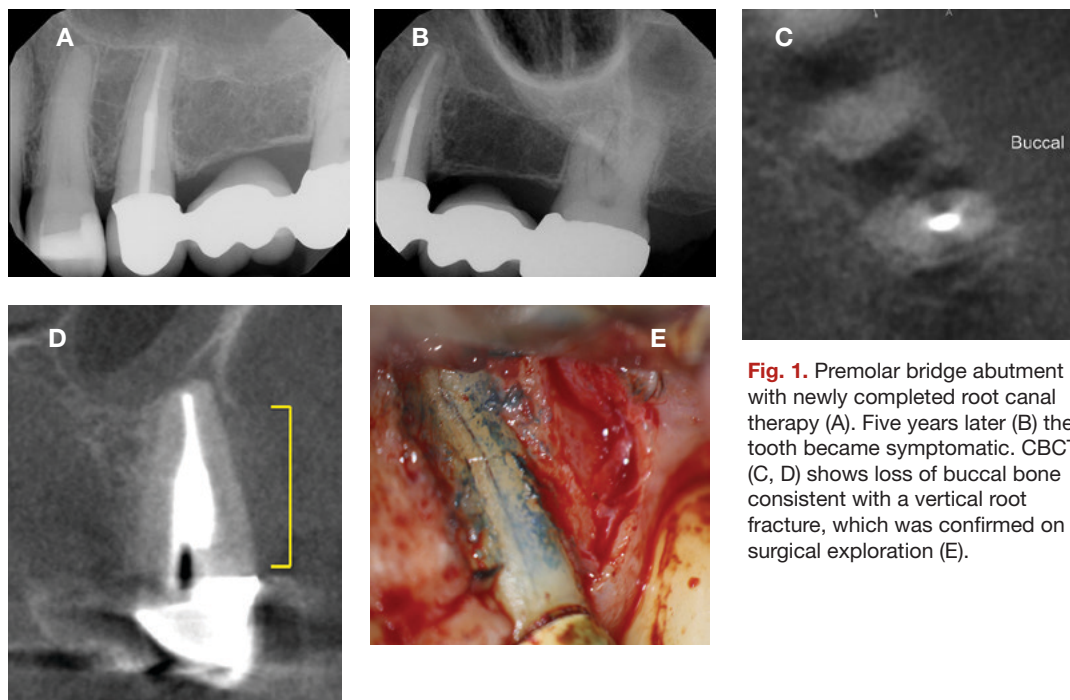


Fig. 1. Premolar bridge abutment with newly completed root canal therapy (A). Five years later (B) the tooth became symptomatic. CBCT (C, D) shows loss of buccal bone consistent with a vertical root fracture, which was confirmed on surgical exploration (E).

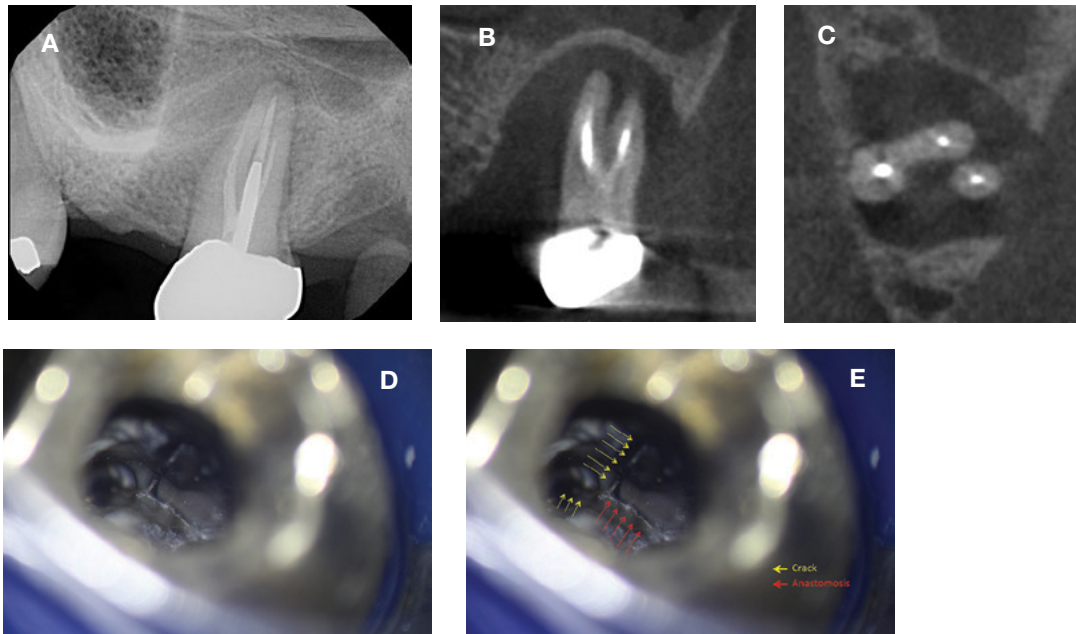


Fig. 2. This asymptomatic molar (A) had extensive bone loss revealed by the CBCT (B, C). Despite the poor prognosis, the patient wanted nonsurgical root canal therapy to attempt to save her tooth. After removing the root filling materials (D), a large vertical fracture (yellow arrows) was found on the mesial wall of the access preparation extending down into the mesio-buccal canal and contacting the mesio-palatal root pulpal anastomosis (red arrows). The prognosis is unfavorable.

Treatment Planning Decisions

There are essentially four options for treatment of a tooth that has post-treatment disease: do nothing, extraction, nonsurgical retreatment, and surgical treatment (10). Avoiding treatment may result in the progression of disease and continued destruction of supporting tissues as well as possible acute exacerbation of systemic side effects such as cellulitis and/or lymphadenopathy. In most cases, these options are unacceptable. Extraction and replacement is a viable option, but replacements for missing teeth rarely are better than an otherwise restorable natural tooth (11), and nonreplacement usually results in unfavorable alterations in the adjacent dentition and surrounding tissues as well as possible diminution of masticatory function. The decision of whether to perform nonsurgical or surgical retreatment to retain the tooth also is complex. The American Association of Endodontists has produced a very helpful publication to help clinicians with these topics, *Treatment Options for the Compromised Tooth: A Decision Guide*, which is available at www.aae.org/treatmentoptions.

For most cases, the clinician needs to decide if retention of the tooth is in the patient's best interest. This decision is based on the restorability of the tooth and its strategic position in the dentition, periodontal health, the health history, motivation and desires of the patient, and the skill level and experience of the dentist.

Generally, the restorability of the tooth is determined by the amount of healthy and intact tooth structure that remains after careful removal of old restorations and caries or resorption. Important treatment planning questions to ask when determining restorability include:

- Does adequate tooth structure remain to allow production of a ferrule for the restorative preparation?
- Will the margins of the potential restoration invade the biologic width?
- Will the remaining tooth structure be strong enough to resist fracture when occlusally loaded?
- Are there any pre-existing tooth fractures or perforations of the root that may compromise the outcome?
- Will crown-lengthening surgery, if necessary (or even possible), expose a furcation or disturb the attachment height of adjacent teeth?
- Is the tooth necessary to keep in order for the patient to masticate effectively and will its loss result in the need for replacement?
- Does the site have adequate bone to retain a possible implant?

Patient factors also are critical in the decision to save or lose a tooth. Is the patient healthy enough to tolerate the treatment options? For example, patients with a history of use of medications to treat osteoporosis and certain types of cancer may be at risk for medication-related osteonecrosis of the jaws (MRONJ) and the risk varies depending on the type of medication (12). In these patients, it is often advisable to avoid extraction surgery and retain the tooth with nonsurgical retreatment. Does the patient smoke or have diabetes? These conditions may affect outcomes of both root canal therapy and implant placement (13-17). Does the patient have the motivation and resources needed to retain a tooth or to place and restore an implant? Does their dental history reveal a problem with maintaining whichever treatment is selected? Can the patient tolerate the long appointment times needed to perform whichever treatment is selected? The clinician must answer these questions to help the patient make the best treatment decision for their particular situation.

Retreatment Procedures

The procedures for endodontic nonsurgical retreatment can be grouped into disassembly, repair of existing perforations, access to missed anatomy, shaping and disinfection of the canal system, and obturation (10). While cleaning, shaping, and disinfecting the root canal space in retreatment can be similar to initial root canal therapy, location and treatment of missed anatomy, disassembly and perforation repair are procedures that are very complex and require a specialized armamentarium and knowledge. The dental operating microscope allows the clinician to visualize the contents of canals and endodontic access preparations better than loupes or the naked eye (18) and supports delicate and important retreatment procedures that cannot be accomplished in any other way. Without the dental operating microscope and 3-D imaging, retreatment at the highest level is very difficult and sometimes impossible to achieve.

Intraoperative decision making generally is very complicated in nonsurgical retreatment, since what one will find inside of a treated tooth may be difficult to discern from the diagnostic data. "Expect the unexpected" is the general rule during retreatment, and the clinician must be prepared to adapt to each unique clinical situation.

An endodontically treated tooth often has a full coverage restoration. The clinician must decide whether to remove the coronal restoration or attempt to retain it by preparing an access through it. Removing an intact restoration with the aim of reusing it can be unpredictable. Most times removal of the restoration is only considered when it needs to be replaced. The simplest approach is usually to prepare the access through the existing restoration, though this does risk damage that may require refabrication (19). It is always prudent to forewarn the patient that retreatment may result in the crown debonding or otherwise being damaged in a way that will require a new restoration.

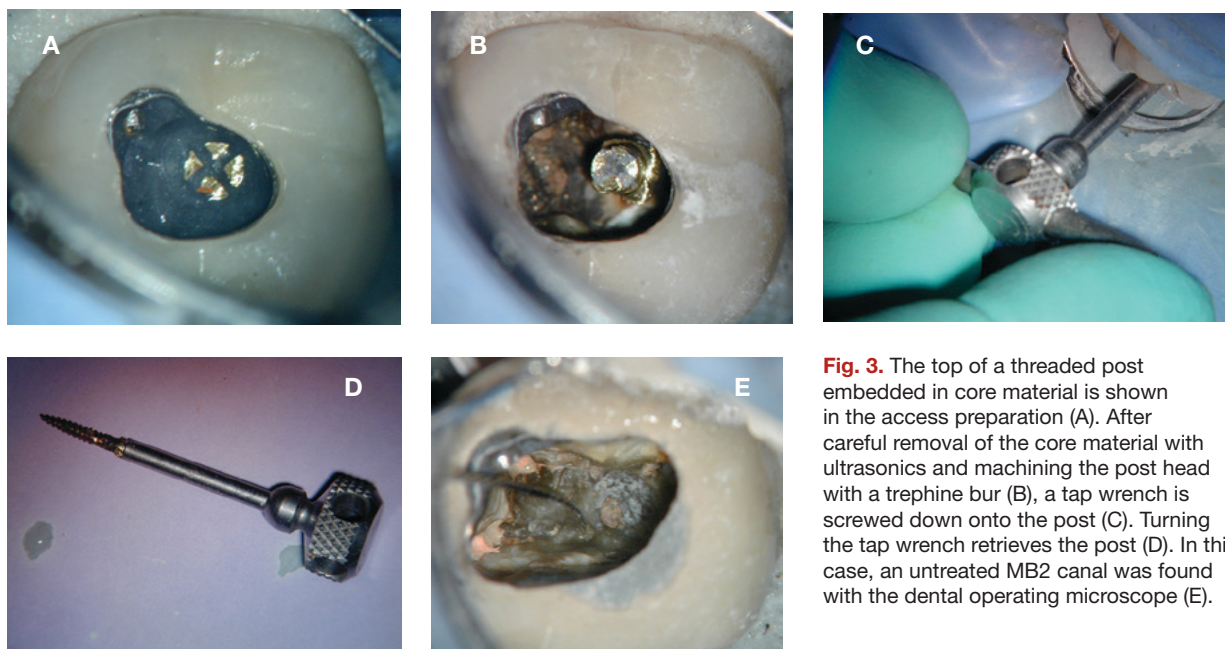


Fig. 3. The top of a threaded post embedded in core material is shown in the access preparation (A). After careful removal of the core material with ultrasonics and machining the post head with a trephine bur (B), a tap wrench is screwed down onto the post (C). Turning the tap wrench retrieves the post (D). In this case, an untreated MB2 canal was found with the dental operating microscope (E).

Generally, if a post and core is present, there is a high likelihood that the coronal restoration will be lost. Endodontists currently use very conservative access preparations to preserve as much tooth structure as possible, but a pre-existing access in a tooth initially treated years ago will usually be larger. In addition, access enlargement often is necessary to excavate around and remove posts in the canals to be retreated. Post removal requires careful use of ultrasonic instruments to remove surrounding core material and disrupt the intracanal cement seal around the post (20). Great care must be taken to avoid overheating the post since heat transmitted to the ligament during post removal may cause large areas of bone destruction and tooth loss (21-23). Intermittent application of the ultrasonic tip with a copious air/water coolant spray is necessary. There are many other types of instruments and techniques that can aid in the removal of a post and the clinician should have training for and access to a wide selection of them to be able to remove posts in all situations (Figure 3).

Following post retrieval, removal of the pre-existing root filling materials is necessary. The techniques used vary depending on the materials that are found in the canals (10). Removal of gutta-percha and solid-core obturators (with plastic or cross-linked gutta-percha carriers) usually is performed with some combination of heat, solvents, and endodontic files and reamers (both manual and engine-driven). Metal solid-core carriers usually require a different procedure since use of engine-driven instruments is contraindicated due to the risk of instrument breakage. Soft paste root fillings require a crown-down technique to minimize extrusion of the potentially toxic paste components into the periradicular tissues, and hard pastes generally are removed with ultrasonics and other solvents. Silver points are removed with endodontic files, forceps, special elevators, or a tube system.

Occasionally, a separated instrument is found in the canal space. The presence of the separated instrument is not a direct cause of post-treatment disease; rather it is necrotic pulp tissue or bacteria in the canal that cannot be removed because the separated instrument prevents disinfection (24). If there is a separated file in the canal, and it is positioned coronal to the canal curvature, many times it can be removed successfully, but this requires very specialized techniques and armamentarium including the dental operating microscope (25). Frequently, removal of tooth structure deep in the canal is required to access and remove the separated instrument. This can result in perforation of the root or weakening of the tooth structure increasing chances of fracture in the future (Figure 4).

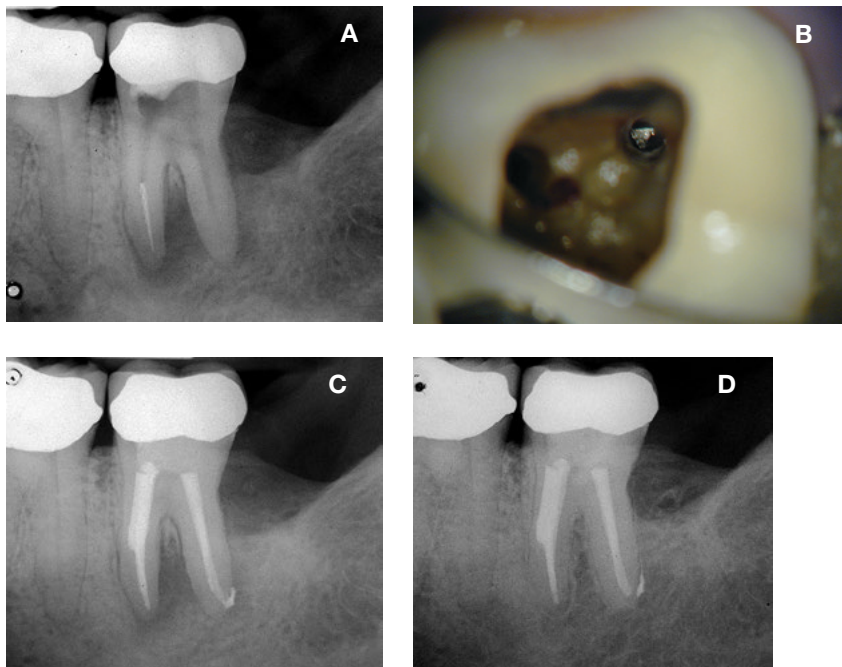


Fig. 4. Removal of a separated instrument from a lower molar (A). The separated instrument is seen in the canal (B) but the enlargement needed to remove it has weakened the root (C). Despite the good healing evident on the two-year re-evaluation (D), the longer-term prognosis is questionable.

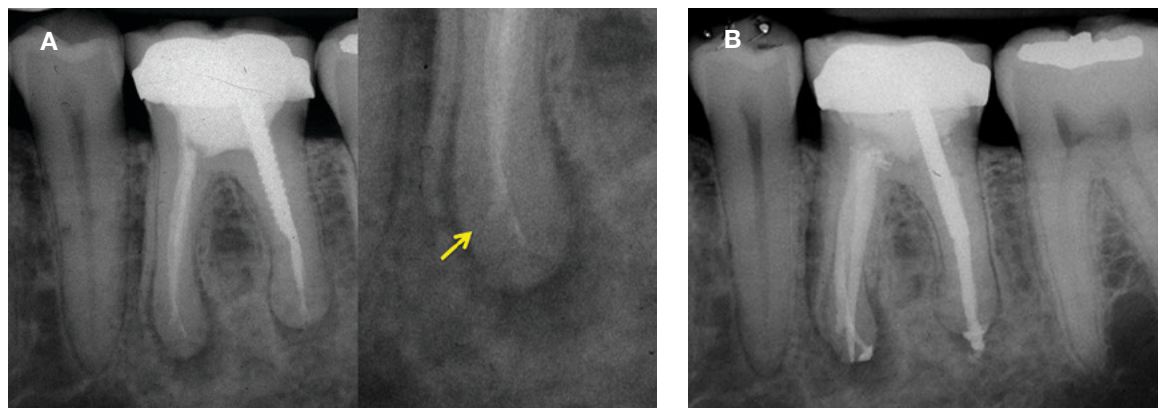


Fig. 5. There is a ledge in the mesial canal of this lower molar (A, arrow). Using pre-bent files, much patience, and time, the ledge was bypassed and the apical canal was three-dimensionally obturated (B).

Root perforations (iatrogenic or resorptive) can cause periradicular periodontitis in root-treated teeth and an assessment of whether the defect can be repaired is part of the treatment planning process. Ideally, the perforation should be repaired as soon as possible (26), and repair of perforations below the periodontal attachment must be done using bioceramic materials to enhance complete healing (27).

After disassembly procedures are completed, the canals should be cleaned thoroughly and made into an ideal shape for reception of new filling materials. This is frequently a complicated process in teeth with post-treatment disease due to iatrogenic canal irregularities (blockages, ledges, zips, and canal transportation) from the previous treatment (28). Bypassing blockages and ledges and thoroughly cleaning and disinfecting zipped or transported apical preparations is very difficult and time consuming (Figure 5) (10). Untreated canal ramifications (such as missed canals and lateral canals) are another challenge that needs to be addressed in retreatment but all of these factors must be managed to create a predictable outcome (29).

The final step in retreatment is to thoroughly disinfect and then three-dimensionally obturate the canal space. When these teeth are handled properly, the complete healing rates for nonsurgical retreatment are high, ranging from 74% - 98% (30) while quality of life and normal mastication is rapidly restored (Figure 6) (31).

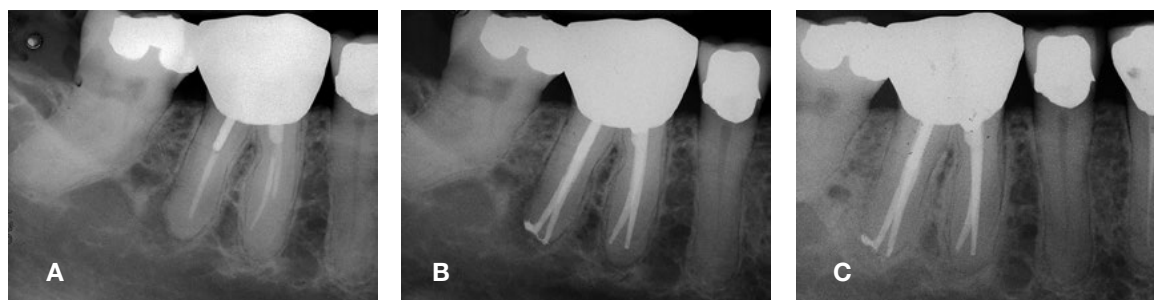


Fig. 6. Previous root canal therapy (A) with symptomatic apical periodontitis due to a missed distal canal and short fills of the mesial canals. Successful nonsurgical retreatment (B) results in complete healing and an asymptomatic patient at the 19-month re-evaluation (C).

For most clinicians, referral to an endodontist will be made if retention of the tooth is the selected treatment choice, since they are the clinicians who are best equipped to make these planning decisions and perform the highly specialized procedures needed to retain the tooth. What may not be so obvious is that the endodontist is also the specialist who can be most helpful in deciding whether the tooth is restorable. Their specialized training in full time post-graduate residency includes not only evidence-based treatment procedures, but also effective diagnosis and treatment planning for teeth with post-treatment disease. Coupled with great experience in “what works,” the endodontist will be the dentist’s most valuable partner in patient care when these hard decisions need to be made.

References

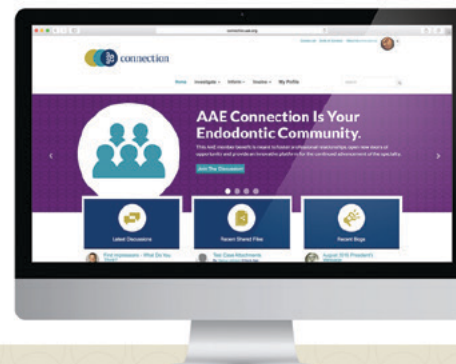1. Sundqvist G, Figdor D. Endodontic treatment of apical periodontitis. In: Orstavik D, Pitt-Ford T, editors. *Essential Endodontology. Prevention and Treatment of Apical Periodontitis*. London: Blackwell Science Ltd; 1998;242.
2. Nair PN. On the causes of persistent apical periodontitis: a review. *Int Endod J* 2006;39:249-81.
3. AAE and AAOMR Joint Position Statement: Use of Cone Beam Computed Tomography in Endodontics 2015 Update. *Oral Surg, Oral Med, Oral Pathol Oral Radiol* 2015;120:508-12.
4. Nudera WJ. Selective Root Retreatment: A Novel Approach. *J Endod* 2015;41:1382-88.
5. Uraba S, Ebihara A, Komatsu K, Ohbayashi N, Okiji T. Ability of Cone-beam Computed Tomography to Detect Periapical Lesions That Were Not Detected by Periapical Radiography: A Retrospective Assessment According to Tooth Group. *J Endod* 2016;42:1186-90.
6. Ee J, Fayad MI, Johnson BR. Comparison of endodontic diagnosis and treatment planning decisions using cone-beam volumetric tomography versus periapical radiography. *J Endod* 2014;40:910-16.
7. Mota de Almeida FJ, Knutsson K, Flygare L. The effect of cone beam CT (CBCT) on therapeutic decision making in endodontics. *Dentomaxillofac Radiol* 2014;43:20130137.
8. Mota de Almeida FJ, Knutsson K, Flygare L. The impact of cone beam computed tomography on the choice of endodontic diagnosis. *IntEndod J* 2015;48:564-72.
9. Cotton TP, Geisler TM, Holden DT, Schwartz SA, Schindler WG. Endodontic applications of cone-beam volumetric tomography. *J Endod* 2007;33:1121-32.
10. Roda R, Gettleman B. Non-surgical Retreatment. In: Hargreaves K, Berman L, eds. *Cohen's Pathways of the Pulp*. 11th ed. 2015; St Louis; Elsevier; 324-86.
11. Iqbal MK, Kim S. For teeth requiring endodontic treatment, what are the differences in outcomes of restored endodontically treated teeth compared to implant-supported restorations? *Int J Oral Maxillofac Implants* 2007;22 Suppl:96-116.
12. Ruggiero SL, Dodson TB, Fantasia J, Goodday R, Aghaloo T, Mehrotra B, et al. American Association of Oral and Maxillofacial Surgeons position paper on medication-related osteonecrosis of the jaw--2014 update. *J Oral Maxillofac Surg* 2014;72:1938-56.
13. Duncan HF, Pitt Ford TR. The potential association between smoking and endodontic disease. *Int Endod J* 2006;39:843-54.
14. Lopez-Lopez J, Jane-Salas E, Martin-Gonzalez J, Castellanos-Cosano L, Llamas-Carreras JM, Velasco-Ortega E, et al. Tobacco smoking and radiographic periapical status: a retrospective case-control study. *J Endod* 2012;38:584-8.
15. Fouad AF, Burleson J. The effect of diabetes mellitus on endodontic treatment outcome: data from an electronic patient record. *J Am Dent Assoc* 2003;134:43-51; quiz 117-8.
16. Segura-Egea JJ, Martin-Gonzalez J, Cabanillas-Balsera D, Fouad AF, Velasco-Ortega E, Lopez-Lopez J. Association between diabetes and the prevalence of radiolucent periapical lesions in root-filled teeth: systematic review and meta-analysis. *Clin Oral Invest* 2016;20:1133-41.
17. Chen H, Liu N, Xu X, Qu X, Lu E. Smoking, radiotherapy, diabetes and osteoporosis as risk factors for dental implant failure: a meta-analysis. *PloS one* 2013;8:e71955.
18. Perrin P, Neuhaus KW, Lussi A. The impact of loupes and microscopes on vision in endodontics. *Int Endod J* 2014;47:425-9.
19. Mulvay PG, Abbott PV. The effect of endodontic access cavity preparation and subsequent restorative procedures on molar crown retention. *Aust Dent J* 1996;41:134-9.
20. Buoncristiani J, Seto BG, Caputo AA. Evaluation of ultrasonic and sonic instruments for intraradicular post removal. *J Endod* 1994;20:486-9.
21. Schwartz RS, Robbins JW. Post placement and restoration of endodontically treated teeth: a literature review. *J Endod* 2004;30:289-301.
22. Budd JC, Gekelman D, White JM. Temperature rise of the post and on the root surface during ultrasonic post removal. *Int Endod J* 2005;38:705-11.
23. Dominici JT, Clark S, Scheetz J, Eleazer PD. Analysis of heat generation using ultrasonic vibration for post removal. *J Endod* 2005;31:301-3.
24. Spili P, Parashos P, Messer HH. The impact of instrument fracture on outcome of endodontic treatment. *J Endod* 2005;31:845-50.
25. Gencoglu N, Helvacioğlu D. Comparison of the different techniques to remove fractured endodontic instruments from root canal systems. *Eur J Dent* 2009;3:90-5.
26. Sinai IH. Endodontic perforations: their prognosis and treatment. *J Am Dent Assoc* 1977;95:90-5.
27. Main C, Mirzayan N, Shabahang S, Torabinejad M. Repair of root perforations using mineral trioxide aggregate: a long-term study. *J Endod* 2004;30:80-3.
28. Jafarzadeh H, Abbott PV. Ledge formation: review of a great challenge in endodontics. *J Endod* 2007;33:1155-62.
29. Farzaneh M, Abitbol S, Friedman S. Treatment Outcome in Endodontics: The Toronto Study. Phases I and II: Orthograde Retreatment. *J Endod* 2004;30:627-33.
30. Friedman S, Mor C. The success of endodontic therapy--healing and functionality. *J Calif Dent Assoc* 2004;32:493-503.
31. He J, White RK, White CA, Schweitzer JL, Woodmansey KF. Clinical and Patient-centered Outcomes of Nonsurgical Root Canal Retreatment in First Molars Using Contemporary Techniques. *J Endod* 2017;43:231-7.



Visit **AAE Connection** to discuss this issue of *Colleagues* and other endodontic topics.

Members, simply click **Log In** from the upper right corner and use your AAE credentials. As you contribute to the conversations, know you are enriching the specialty as you collaborate with your peers from around the globe.

Visit connection.aae.org to join the discussion!



AAE Connection is an exclusive, members-only online community.

Not an AAE Member?

Check out all of the benefits membership has to offer and **join today** at www.aae.org/join.

The AAE wishes to thank Dr. Robert S. Roda for authoring this issue of the newsletter, as well the following article reviewers: Drs. Scott L. Doyle, Steven J. Katz, Linda G. Levin, Avina K. Paranjpe and Patrick E. Taylor.

Online Bonus Materials: Nonsurgical Retreatment

This issue of the *Colleagues* newsletter is available online at www.aae.org/colleagues with the following bonus materials:

- Full-Text Article: He J, White RK, White CA, Schweitzer JL, Woodmansey KF. Clinical and Patient-centered Outcomes of Nonsurgical Root Canal Retreatment in First Molars Using Contemporary Techniques. *J Endod* 2017;43:231-7.
- Treatment Options for the Compromised Tooth: A Decision Guide
- AAE/AAOMR Revised Joint Position Statement on Cone Beam Computed Tomography in Endodontics
- Contemporary Endodontic Technology: Cone Beam Imaging in Treatment Planning



211 E. Chicago Ave., Suite 1100
Chicago, IL 60611-2691
Phone: 800-872-3636 (U.S., Canada, Mexico)
or 312-266-7255
Fax: 866-451-9020 (U.S., Canada, Mexico)
or 312-266-9867
Email: info@aae.org



facebook.com/endodontists



[@SavingYourTeeth](https://twitter.com/SavingYourTeeth)



youtube.com/rootcanalspecialists



www.aae.org

© 2017

American Association of Endodontists (AAE),
All Rights Reserved



Earn online CE credit when you enjoy
two articles from *Colleagues for Excellence*!

www.aae.org/LiveLearningCenter

Information in this newsletter is designed to aid dentists. Practitioners must use their best professional judgment, taking into account the needs of each individual patient when making diagnosis/treatment plans. The AAE neither expressly nor implicitly warrants against any negative results associated with the application of this information. If you would like more information, consult your endodontic colleague or contact the AAE.

Did you enjoy this issue of *Colleagues*?

Are there topics you would like to cover in the future? We want to hear from you! Send your comments and questions to the American Association of Endodontists at the address below, and visit the *Colleagues* online archive at www.aae.org/colleagues for back issues of the newsletter.