



National
Comprehensive
Cancer
Network®

NCCN Clinical Practice Guidelines in Oncology (NCCN Guidelines®)

Penile Cancer

Version 2.2017 — March 10, 2017

NCCN.org

Continue



National
Comprehensive
Cancer
Network®

NCCN Guidelines Version 2.2017 Panel Members

Penile Cancer

[NCCN Guidelines Index](#)
[Table of Contents](#)
[Discussion](#)

* Peter E. Clark, MD ☐ Chair
Vanderbilt-Ingram Cancer Center

* Philippe E. Spiess, MD, MS ☐ Vice chair
Moffitt Cancer Center

Neeraj Agarwal, MD ‡ †
Huntsman Cancer Institute
at the University of Utah

Rick Bangs, MBA
Patient Advocate

Stephen A. Boorjian, MD ☐
Mayo Clinic Cancer Center

Mark K. Buyyounouski, MD, MS §
Stanford Cancer Institute

Tracy M. Downs, MD ☐
University of Wisconsin Carbone Cancer Center

Jason A. Efstathiou, MD, DPhil §
Massachusetts General Hospital Cancer Center

Thomas W. Flaig, MD †
University of Colorado Cancer Center

Terence Friedlander, MD †
UCSF Helen Diller Family
Comprehensive Cancer Center

Richard E. Greenberg, MD ☐
Fox Chase Cancer Center

Khurshid A. Guru, MD ☐
Roswell Park Cancer Institute

Noah Hahn, MD †
The Sidney Kimmel Comprehensive
Cancer Center at Johns Hopkins

Harry W. Herr, MD ☐
Memorial Sloan Kettering Cancer Center

[NCCN Guidelines Panel Disclosures](#)

Christopher Hoimes, MD †
Case Comprehensive Cancer Center/
University Hospitals Seidman Cancer Center
and Cleveland Clinic Taussig Cancer Institute

Brant A. Inman, MD, MSc ☐
Duke Cancer Institute

Masahito Jimbo, MD, PhD, MPH
University of Michigan
Comprehensive Cancer Center

A. Karim Kader, MD, PhD ☐
UC San Diego Moores Cancer Center

Subodh M. Lele, MD ≠
Fred & Pamela Buffett Cancer Center

Joshua J. Meeks, MD, PhD ☐
Robert H. Lurie Comprehensive Cancer
Center of Northwestern University

Jeff Michalski, MD, MBA §
Siteman Cancer Center at Barnes-
Jewish Hospital and Washington
University School of Medicine

Jeffrey S. Montgomery, MD, MHSA ☐
University of Michigan
Comprehensive Cancer Center

Lance C. Pagliaro, MD †
Mayo Clinic Cancer Center

Sumanta K. Pal, MD †
City of Hope Comprehensive Cancer Center

Anthony Patterson, MD ☐
St. Jude Children's Research Hospital/
University of Tennessee Health Science Center

Elizabeth R. Plimack, MD, MS †
Fox Chase Cancer Center

Kamal S. Pohar, MD ☐
The Ohio State University Comprehensive
Cancer Center - James Cancer Hospital
and Solove Research Institute

Michael P. Porter, MD, MS ☐
Fred Hutchinson Cancer Research Center/
Seattle Cancer Care Alliance

Mark A. Preston, MD, MPH ☐
Dana-Farber/Brigham and Women's
Cancer Center

Wade J. Sexton, MD ☐
Moffitt Cancer Center

Arlene O. Siefker-Radtke, MD †
The University of Texas
MD Anderson Cancer Center

Guru Sonpavde, MD †
University of Alabama at Birmingham
Comprehensive Cancer Center

Jonathan Tward, MD, PhD §
Huntsman Cancer Institute
at the University of Utah

Geoffrey Wile, MD ☐
Vanderbilt-Ingram Cancer Center

NCCN
Mary Dwyer, MS
Courtney Smith, PhD

Continue

☐ Urology	☐ Diagnostic radiology
† Medical oncology	≠ Pathology
‡ Hematology/Hematology oncology	* Discussion writing
§ Radiotherapy/Radiation oncology	committee member



National
Comprehensive
Cancer
Network®

NCCN Guidelines Version 2.2017 Table of Contents

Penile Cancer

[NCCN Guidelines Index](#)
[Table of Contents](#)
[Discussion](#)

[NCCN Penile Cancer Panel Members](#)
[Summary of the Guidelines Updates](#)

[Primary Evaluation, Clinical Diagnosis \(PN-1\)](#)

[Primary Treatment Tis, Ta \(PN-1\)](#)

[Primary Treatment T1, T2 or Greater \(PN-2\)](#)

[Management of Non-Palpable Inguinal Lymph Nodes \(PN-3\)](#)

[Management of Palpable Non-Bulky Inguinal Lymph Nodes \(PN-4\)](#)

[Management of Palpable Bulky Inguinal Lymph Nodes \(PN-5\)](#)

[Management of Enlarged Pelvic Lymph Nodes \(PN-6\)](#)

[Surveillance Schedule \(PN-7\)](#)

[Management of Recurrent Disease \(PN-8\)](#)

[Management of Metastatic Disease \(PN-9\)](#)

[Principles of Penile Organ-Sparing Approaches \(PN-A\)](#)

[Principles of Surgery \(PN-B\)](#)

[Principles of Radiotherapy \(PN-C\)](#)

[Principles of Chemotherapy \(PN-D\)](#)

[Staging \(ST-1\)](#)

Clinical Trials: NCCN believes that the best management for any patient with cancer is in a clinical trial. Participation in clinical trials is especially encouraged.

To find clinical trials online at NCCN Member Institutions, [click here:
nccn.org/clinical_trials/physician.html](#).

NCCN Categories of Evidence and Consensus: All recommendations are category 2A unless otherwise specified.

See [NCCN Categories of Evidence and Consensus](#).

The NCCN Guidelines® are a statement of evidence and consensus of the authors regarding their views of currently accepted approaches to treatment. Any clinician seeking to apply or consult the NCCN Guidelines is expected to use independent medical judgment in the context of individual clinical circumstances to determine any patient's care or treatment. The National Comprehensive Cancer Network® (NCCN®) makes no representations or warranties of any kind regarding their content, use or application and disclaims any responsibility for their application or use in any way. The NCCN Guidelines are copyrighted by National Comprehensive Cancer Network®. All rights reserved. The NCCN Guidelines and the illustrations herein may not be reproduced in any form without the express written permission of NCCN. ©2017.



NCCN Guidelines Version 2.2017 Updates

Penile Cancer

Updates in Version 2.2017 of the NCCN Guidelines for Penile Cancer from Version 1.2017 include:

MS-1

- The discussion section was updated to reflect the changes in the algorithm.

Updates in Version 1.2017 of the NCCN Guidelines for Penile Cancer from Version 2.2016 include:

General

- Imaging recommendations for “with contrast” were added as appropriate throughout the guidelines.
- Second-line therapy was changed to Subsequent therapy as appropriate throughout the guidelines.
- The following footnotes were removed and added to the new Principles of Penile Organ-Sparing Approaches and Principles of Surgery or the content was added to the algorithm:
 - ▶ Topical therapy may include topical imiquimod (5%) or 5-fluorouracil (5-FU) cream.
 - ▶ Moh’s surgery is an option.
 - ▶ Complete excision of the skin with a wide negative margin with skin grafting as needed. STSG = split-thickness skin graft; FTSG = full-thickness skin graft.
 - ▶ Recommend intraoperative frozen sections to achieve negative margins.
 - ▶ Appropriate with proven negative margins for tumors involving the glans only.
 - ▶ When it is necessary to dissect into the corpora cavernosum to achieve a negative margin, a partial or total penectomy is performed.

PN-1

- Primary treatment
 - ▶ 2nd option was revised, “Wide local excision ~~including~~ circumcision.”
 - ▶ 5th option was added, “Mohs surgery in select cases (category 2B).”

PN-2

- Primary treatment
 - ▶ T1, grade 1-2,
 - ◊ 2nd option was added, “Glansectomy in select cases.”
 - ◊ 3rd option was added, “Mohs surgery in select cases (category 2B).”
 - ▶ T1, grade 3-4,
 - ◊ “Glansectomy” was removed.

PN-3

- Risk stratification based on primary lesion
 - ▶ Intermediate risk (T1b, Grade 1 or 2) or High risk (T1b, Grade 3 or 4; Any T2 or greater) was changed to
 - ◊ Intermediate/High risk
 - T1b
 - Any T2 or greater
- Footnotes
 - ▶ Footnote e was revised, “Ta verrucous carcinoma ... *Therefore, only and would require surveillance alone of the inguinal lymph nodes is required.*”
 - ▶ Footnote j was clarified, “Consider prophylactic EBRT (category 2B) to inguinal lymph nodes...”

PN-4

- Management of Palpable Non-Bulky Inguinal Lymph Nodes, the following risk stratification groups were clarified by adding, “Unilateral lymph node(s) <4 cm (fixed).” (Also for PN-5)
- For non-bulky, unilateral lymph node(s) <4 cm (mobile),
 - ◊ Low-risk primary lesion, “lymph node biopsy” was clarified as “percutaneous lymph node biopsy.”
 - ◊ High-risk primary lesion, after treatment with ILND, options for pN2-3 disease were revised by adding, “Pelvic lymph node dissection (PLND) ± adjuvant chemotherapy or chemoradiotherapy (category 2B).”
- Footnotes
 - ▶ Footnote k was added, “CT/MRI of pelvis with contrast for nodal evaluation if difficult to assess on physical exam.”
 - ▶ Footnote p was added, “Ultrasound- or CT-guided biopsy.” (Also for PN-5, 6, and 8)

PN-5

- Under lymph nodes, “needle biopsy” was clarified as “percutaneous lymph node biopsy.”

PN-6

- Pelvic lymph nodes enlarged, “needle biopsy” was revised as, “Percutaneous lymph node biopsy, if technically feasible.”
- For disease progression or non-resectable after treatment with neoadjuvant chemotherapy, “Additional systemic chemotherapy with consideration of radiation therapy for local control or Clinical trial” was replaced with a link to “See No response/Disease Progression on Management of Metastatic Disease (PN-9).”
- Footnote u was added, “If not technically feasible, PET/CT scan can be used to evaluate lymph nodes.”

[Continued on
next page](#)

Note: All recommendations are category 2A unless otherwise indicated.

Clinical Trials: NCCN believes that the best management of any patient with cancer is in a clinical trial. Participation in clinical trials is especially encouraged.



NCCN Guidelines Version 2.2017 Updates

Penile Cancer

Updates in Version 1.2017 of the NCCN Guidelines for Penile Cancer from Version 2.2016 include:

PN-7

- Primary lesion,
 - ▶ The possible initial treatment options were clarified,
 - ◊ Topical therapy
 - ◊ Laser therapy
 - ◊ Radiation/*Chemoradiation* therapy
 - ◊ Wide local excision ~~including circumcision~~
 - ◊ *Glansectomy*
 - ◊ *Mohs surgery*

PN-8

- Local recurrence in inguinal region, the algorithm was extensively revised.

Principles of Penile Organ-Sparing Approaches

PN-A

- The Principles of Organ-Sparing Approaches was separated out from the Principles of Surgery.
- Topical therapy, dosing was added for patients with Tis or Ta disease:
 - ▶ Imiquimod 5%, apply at night three times per week for 4–16 weeks
 - ▶ 5-FU cream 5%, apply twice daily for 2–6 weeks
- Laser therapy, 4 new bullets were added along with a table of the therapeutic lasers commonly used to treat penile cancer including suggested settings.
- Bullets regarding wide local excision, glansectomy, and Mohs microscopic surgery were added.

Principles of Surgery

PN-B

- Penectomy,
 - ▶ 1st bullet was revised by adding, “If a partial penectomy is not possible, a total penectomy should be performed.”
 - ▶ 2nd bullet was added, “Partial or total penectomy when invasion into the corpora cavernosum is necessary to achieve a negative margin.”
 - ▶ 3rd bullet was added, “Intraoperative frozen sections are recommended to determine negative margins.”

Principles of Surgery (continued)

- Surgical Management of Inguinal and Pelvic Lymph Nodes
 - ▶ 2nd bullet was added, “DSNB is only recommended if the treating physician has experience with this modality.”
 - ▶ 3rd bullet was added, “If positive lymph nodes are found on DSNB, ILND is recommended.”
 - ▶ 4th bullet was revised “PLND should be considered at the time *or following* ILND in patients with ≥ 2 *positive* inguinal nodes ~~(on frozen section)~~ on the ipsilateral ILND site ~~or in a delayed procedure in patients with extranodal extension or in the presence of extranodal extension on final pathological review.~~”
 - ▶ 5th bullet was added, “A bilateral PLND should be considered either at the time or following ILND in patients with ≥ 4 positive inguinal nodes (in total among both sides).”

Principles of Radiotherapy

PN-C

- Primary Radiation/*Chemoradiation* Therapy, for T1-2, N0, If tumor < 4 cm,
 - ▶ “preferred approach” was removed from “Brachytherapy alone” and clarified as a category 2B recommendation.
 - ▶ EBRT was clarified as a category 2B recommendation and EBRT with concurrent chemotherapy was clarified as a category 3 recommendation.
- Heading for “Primary Site Margin Positive” was clarified by adding, “Following Penectomy.”
 - ▶ 1st sub-bullet was revised, “*Postsurgical scar* EBRT: 60–70 Gy to the primary tumor site and surgical scar (for close margin *observation may be considered*) ~~consider radiation treatment vs. observation.~~”
- Heading for adjuvant radiotherapy was clarified as, “~~Postoperative~~ Adjuvant Chemoradiotherapy”
 - ▶ 1st bullet was revised as, “Inguinal *and/or* Pelvic Lymph Node Positive.”
 - ◊ 1st sub-bullet was added, “Recommended for palpable bulky inguinal lymph nodes or enlarged pelvic lymph nodes (category 2A); Consider for palpable non-bulky inguinal lymph nodes pN2-3 disease (category 2B) or for local recurrence to inguinal region (category 2B).”
 - ◊ 2nd sub-bullet was revised as, “Inguinal and pelvic lymph node EBRT to 45–50.4 Gy ~~(strongly consider concurrent chemotherapy).~~”

[Continued on
next page](#)

Note: All recommendations are category 2A unless otherwise indicated.

Clinical Trials: NCCN believes that the best management of any patient with cancer is in a clinical trial. Participation in clinical trials is especially encouraged.



National
Comprehensive
Cancer
Network®

NCCN Guidelines Version 2.2017 Updates

Penile Cancer

[NCCN Guidelines Index](#)
[Table of Contents](#)
[Discussion](#)

Updates in Version 1.2017 of the NCCN Guidelines for Penile Cancer from Version 2.2016 include:

Principles of Chemotherapy

PN-D 1 of 2

- Neoadjuvant Chemotherapy Prior to ILND or PLND
 - › 1st bullet was revised from “Neoadjuvant, cisplatin-based chemotherapy...” to “Neoadjuvant chemotherapy with TIP (paclitaxel, ifosfamide, and cisplatin)...”
- Adjuvant Chemotherapy Following ILND or PLND
 - › 1st bullet was revised by adding, “5-FU plus cisplatin can be considered as an alternative to TIP in the adjuvant setting.”

PN-D 2 of 2

- TIP, “preferred” was added.
- 5-FU + cisplatin, “(not recommended for neoadjuvant setting)” was added and dosing was updated.

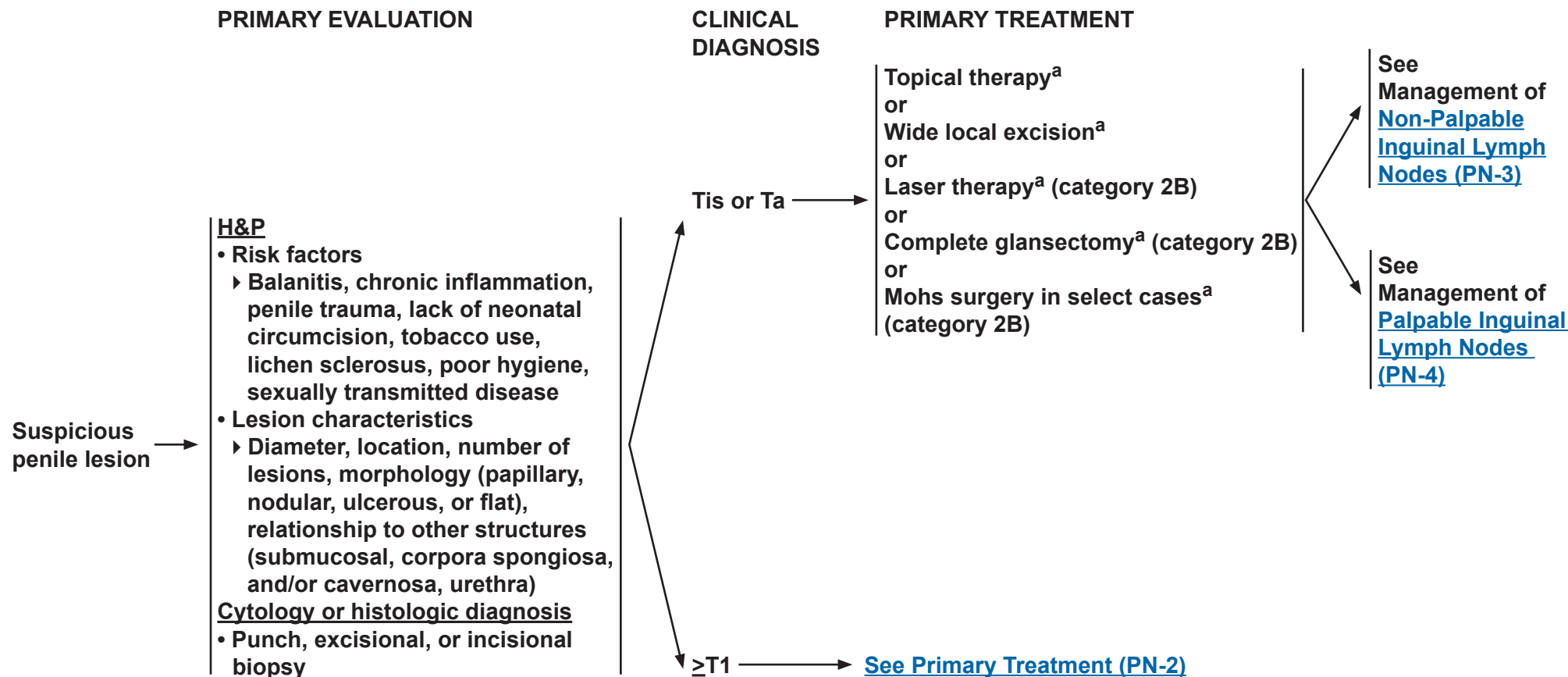
Note: All recommendations are category 2A unless otherwise indicated.

Clinical Trials: NCCN believes that the best management of any patient with cancer is in a clinical trial. Participation in clinical trials is especially encouraged.



NCCN Guidelines Version 2.2017

Penile Cancer



If recurrent disease, [see PN-8](#) or
if metastatic disease, [see PN-9](#)

^a[See Principles of Penile Organ-Sparing Approaches \(PN-A\).](#)

Note: All recommendations are category 2A unless otherwise indicated.

Clinical Trials: NCCN believes that the best management of any patient with cancer is in a clinical trial. Participation in clinical trials is especially encouraged.

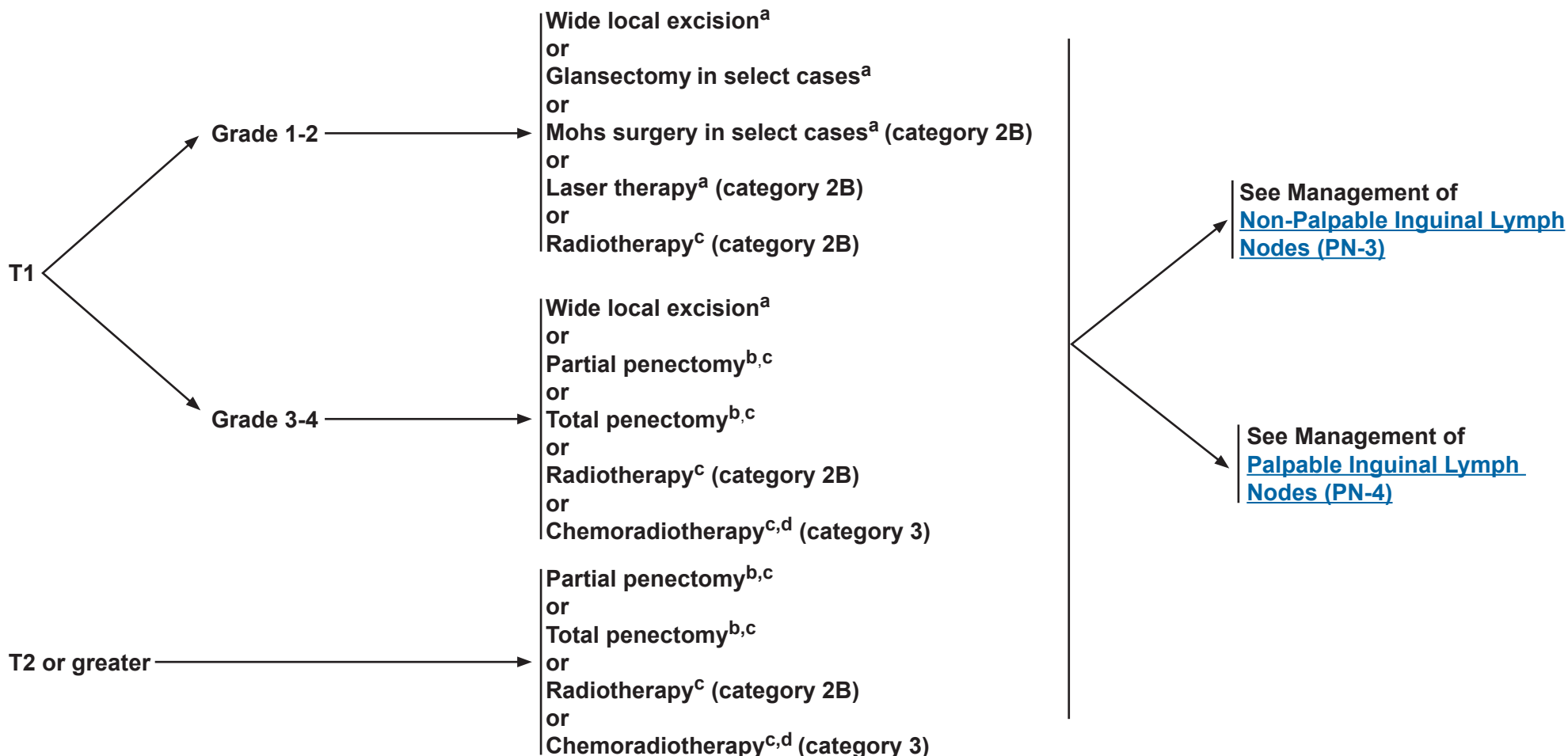


NCCN Guidelines Version 2.2017

Penile Cancer

PATHOLOGIC DIAGNOSIS

PRIMARY TREATMENT



^aSee Principles of Penile Organ-Sparing Approaches (PN-A).

^bSee Principles of Surgery (PN-B).

^cSee Principles of Radiotherapy (PN-C).

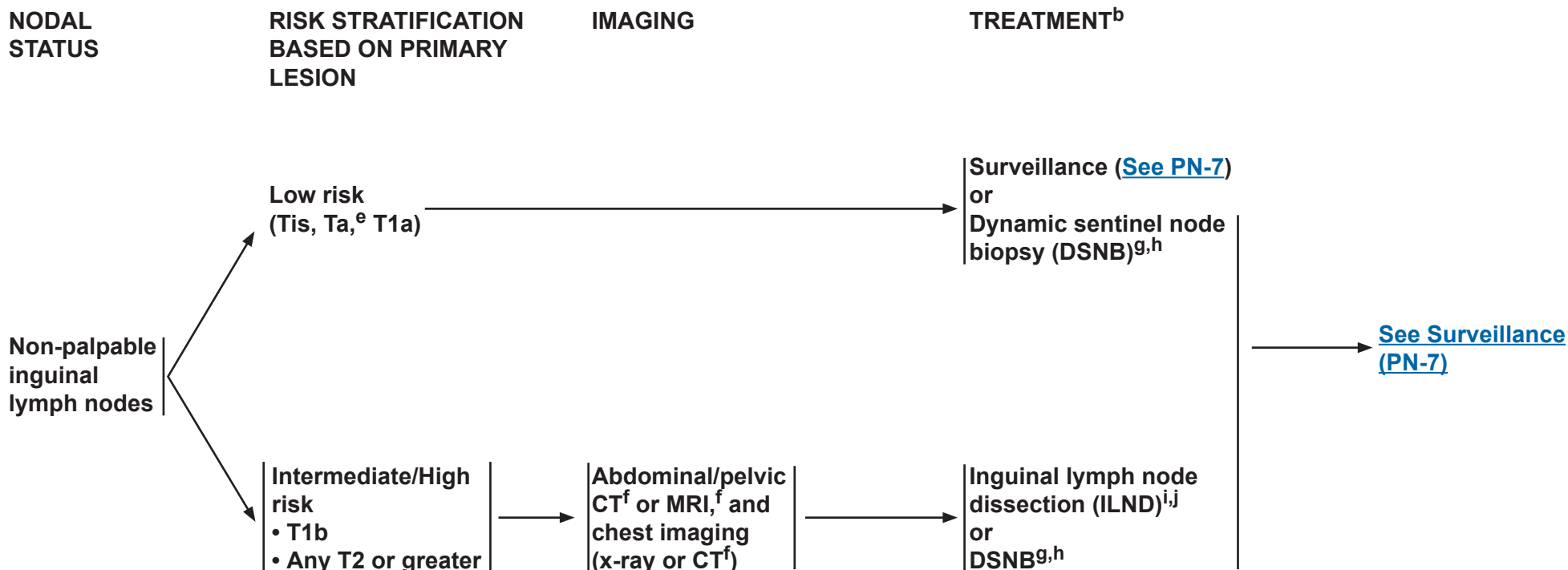
^dSee Principles of Chemotherapy (PN-D).

Note: All recommendations are category 2A unless otherwise indicated.

Clinical Trials: NCCN believes that the best management of any patient with cancer is in a clinical trial. Participation in clinical trials is especially encouraged.



MANAGEMENT OF NON-PALPABLE INGUINAL LYMPH NODES



^b[See Principles of Surgery \(PN-B\).](#)

^eTa verrucous carcinoma is by definition a well-differentiated tumor. Therefore, only surveillance of the inguinal lymph nodes is required.

^fWith contrast unless contraindicated.

^gDSNB is recommended provided the treating physician has experience with this modality.

^hIf positive lymph nodes are found on DSNB, ILND is recommended.

ⁱA modified/superficial inguinal dissection with intraoperative frozen section is an acceptable alternative to stage the inguinal lymph nodes.

^jConsider prophylactic EBRT (category 2B) to inguinal lymph nodes in patients who are not surgical candidates or who decline surgical management.

Note: All recommendations are category 2A unless otherwise indicated.

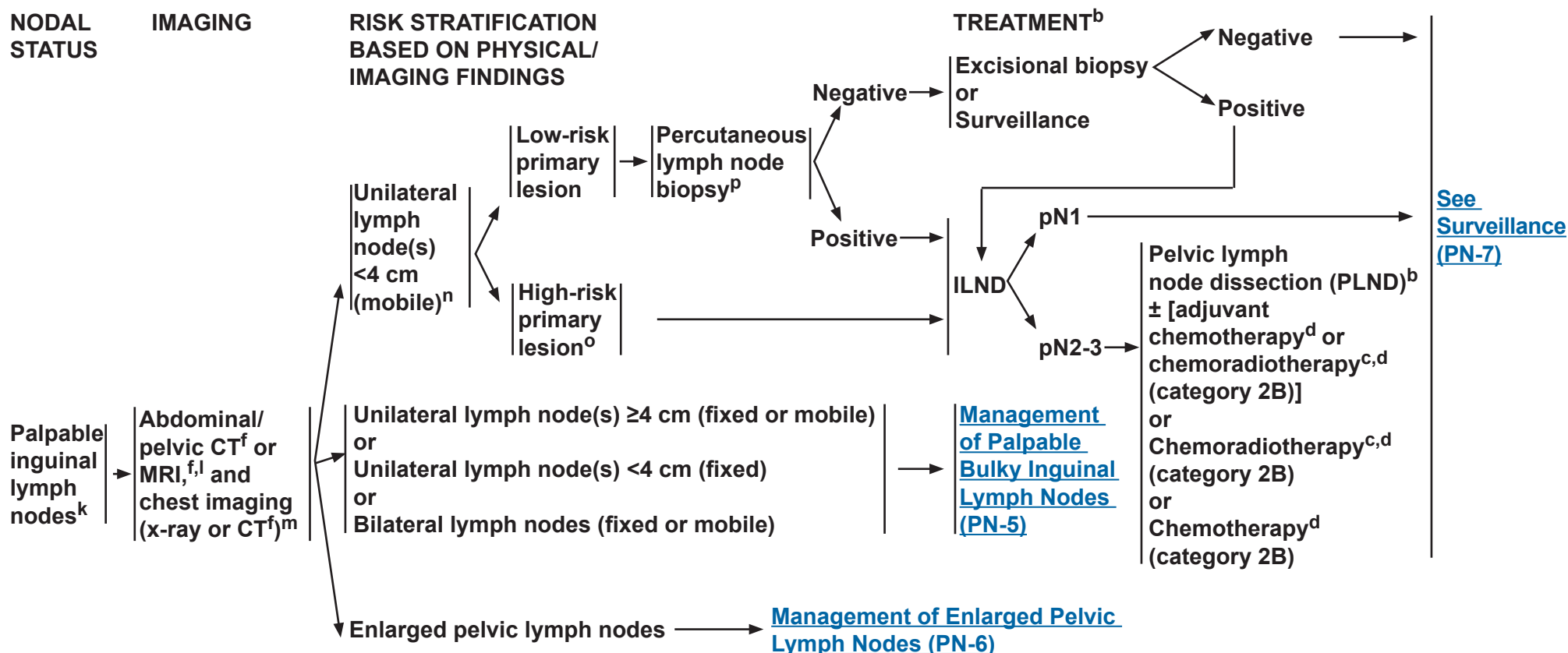
Clinical Trials: NCCN believes that the best management of any patient with cancer is in a clinical trial. Participation in clinical trials is especially encouraged.



NCCN Guidelines Version 2.2017

Penile Cancer

MANAGEMENT OF PALPABLE NON-BULKY INGUINAL LYMPH NODES


^bSee Principles of Surgery (PN-B).

^cSee Principles of Radiotherapy (PN-C).

^dSee Principles of Chemotherapy (PN-D).

^fWith contrast unless contraindicated.

^kCT/MRI of pelvis with contrast for nodal evaluation if difficult to assess on physical exam.

^lConsider PET/CT scan.

^mIf M1 disease identified, see [Management of Metastatic Disease \(PN-9\)](#).

ⁿThe size threshold of 4 cm represents the largest diameter of contiguous inguinal lymph node(s) tissue as measured on either physical examination and/or axial imaging (CT or MRI) and suspected of harboring metastatic disease.

^oHigh-risk primary lesion: T1, high-grade, lymphovascular invasion, >50% poorly undifferentiated.

^pUltrasound- or CT-guided biopsy.

Note: All recommendations are category 2A unless otherwise indicated.

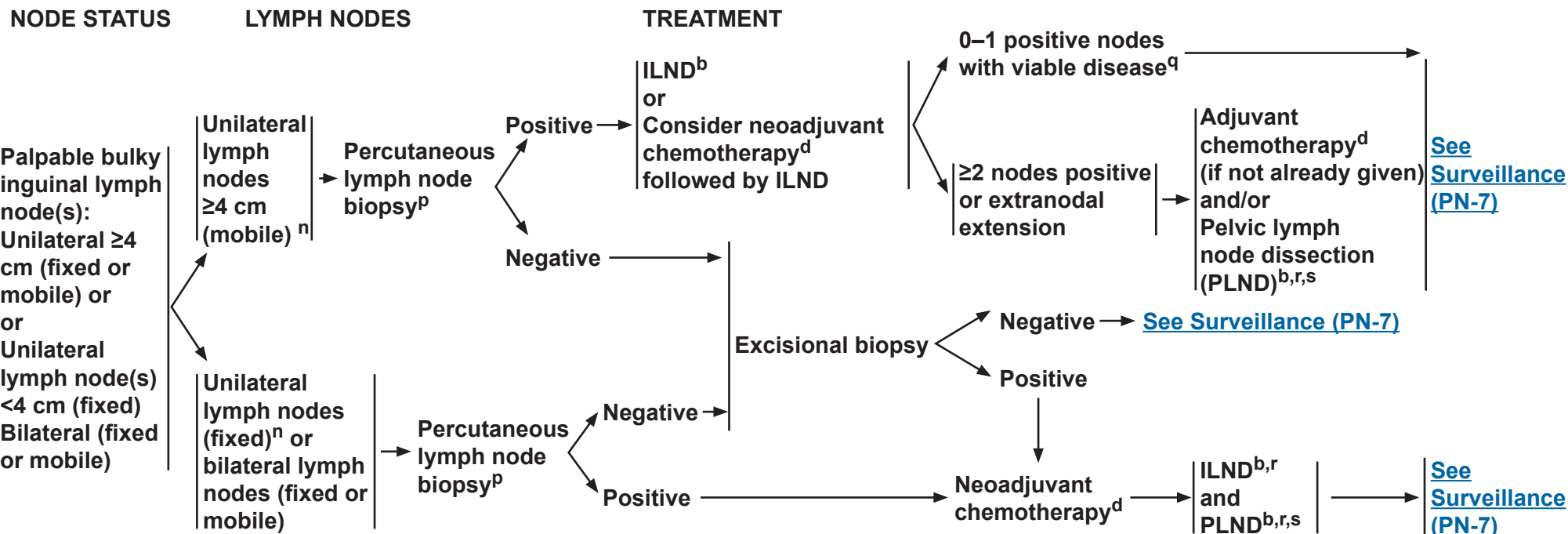
Clinical Trials: NCCN believes that the best management of any patient with cancer is in a clinical trial. Participation in clinical trials is especially encouraged.



NCCN Guidelines Version 2.2017

Penile Cancer

MANAGEMENT OF PALPABLE BULKY INGUINAL LYMPH NODES


^bSee Principles of Surgery (PN-B).

^dSee Principles of Chemotherapy (PN-D).

ⁿThe size threshold of 4 cm represents the largest diameter of contiguous inguinal lymph node(s) tissue as measured on either physical examination and/or axial imaging (CT or MRI) and suspected of harboring metastatic disease.

^pUltrasound- or CT-guided biopsy.

^qFor viable disease post-chemotherapy, consider PLND.

^rConsider postoperative radiotherapy or chemoradiotherapy.

^sData suggest that in the setting of ≥4 positive inguinal lymph nodes, bilateral PLND should be performed. Zargar-Shoshtari K, Djajadiningrat R, Sharma P, et al. Establishing criteria for bilateral pelvic lymph node dissection in the management of penile cancer: lessons learned from an international multicenter collaboration. J Urol 2015;194:696-701.

Note: All recommendations are category 2A unless otherwise indicated.

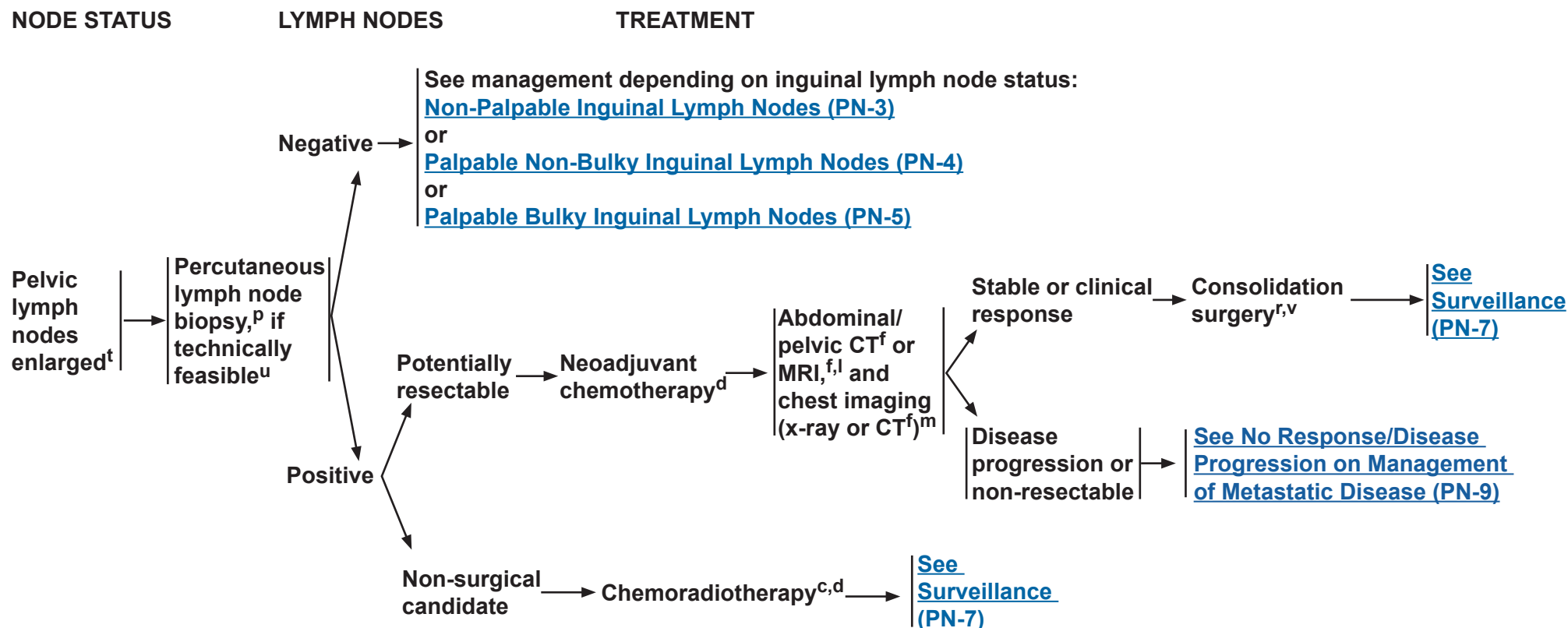
Clinical Trials: NCCN believes that the best management of any patient with cancer is in a clinical trial. Participation in clinical trials is especially encouraged.



NCCN Guidelines Version 2.2017

Penile Cancer

MANAGEMENT OF ENLARGED PELVIC LYMPH NODES



^cSee [Principles of Radiotherapy \(PN-C\)](#).

^dSee [Principles of Chemotherapy \(PN-D\)](#).

^fWith contrast unless contraindicated.

^lConsider PET/CT scan.

^mIf M1 disease identified, see [Management of Metastatic Disease \(PN-9\)](#).

^pUltrasound- or CT-guided biopsy.

^rConsider postoperative radiotherapy or chemoradiotherapy.

^tOn CT or MRI, not pathologic stage.

^uIf not technically feasible, PET/CT scan can be used to evaluate lymph nodes.

^vConsolidation surgery consists of bilateral superficial and deep ILND and unilateral/bilateral PLND.

Note: All recommendations are category 2A unless otherwise indicated.

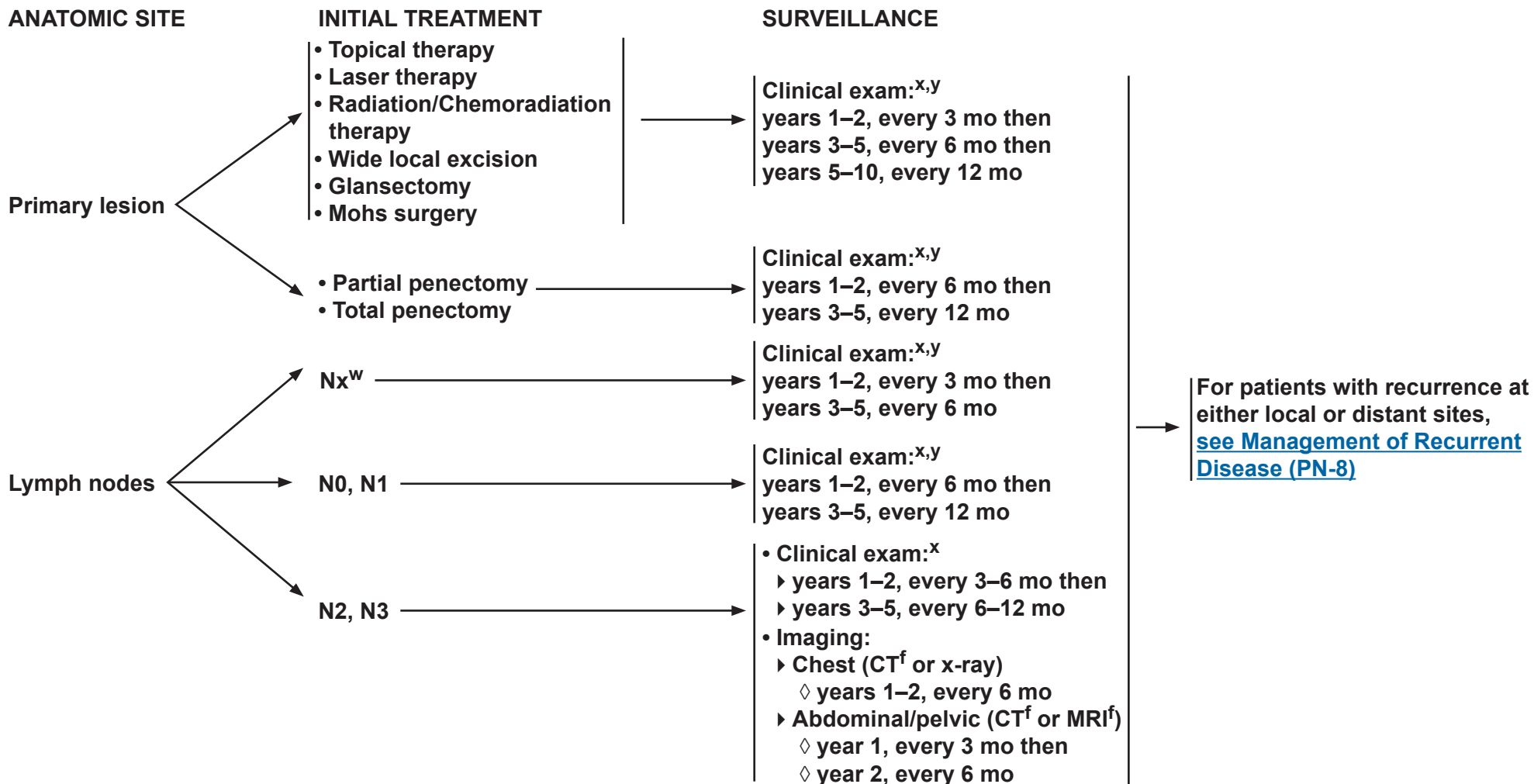
Clinical Trials: NCCN believes that the best management of any patient with cancer is in a clinical trial. Participation in clinical trials is especially encouraged.



NCCN Guidelines Version 2.2017

Penile Cancer

SURVEILLANCE SCHEDULE



^fWith contrast unless contraindicated.

^wPatients on active surveillance of clinically negative nodes and at low risk for inguinal metastases.

^xClinical exam includes examination of the penis and inguinal region.

^yIf an abnormal clinical exam, obese patient, or prior inguinal surgery, then ultrasound, CT with contrast, or MRI with contrast of the inguinal region can be considered.

Note: All recommendations are category 2A unless otherwise indicated.

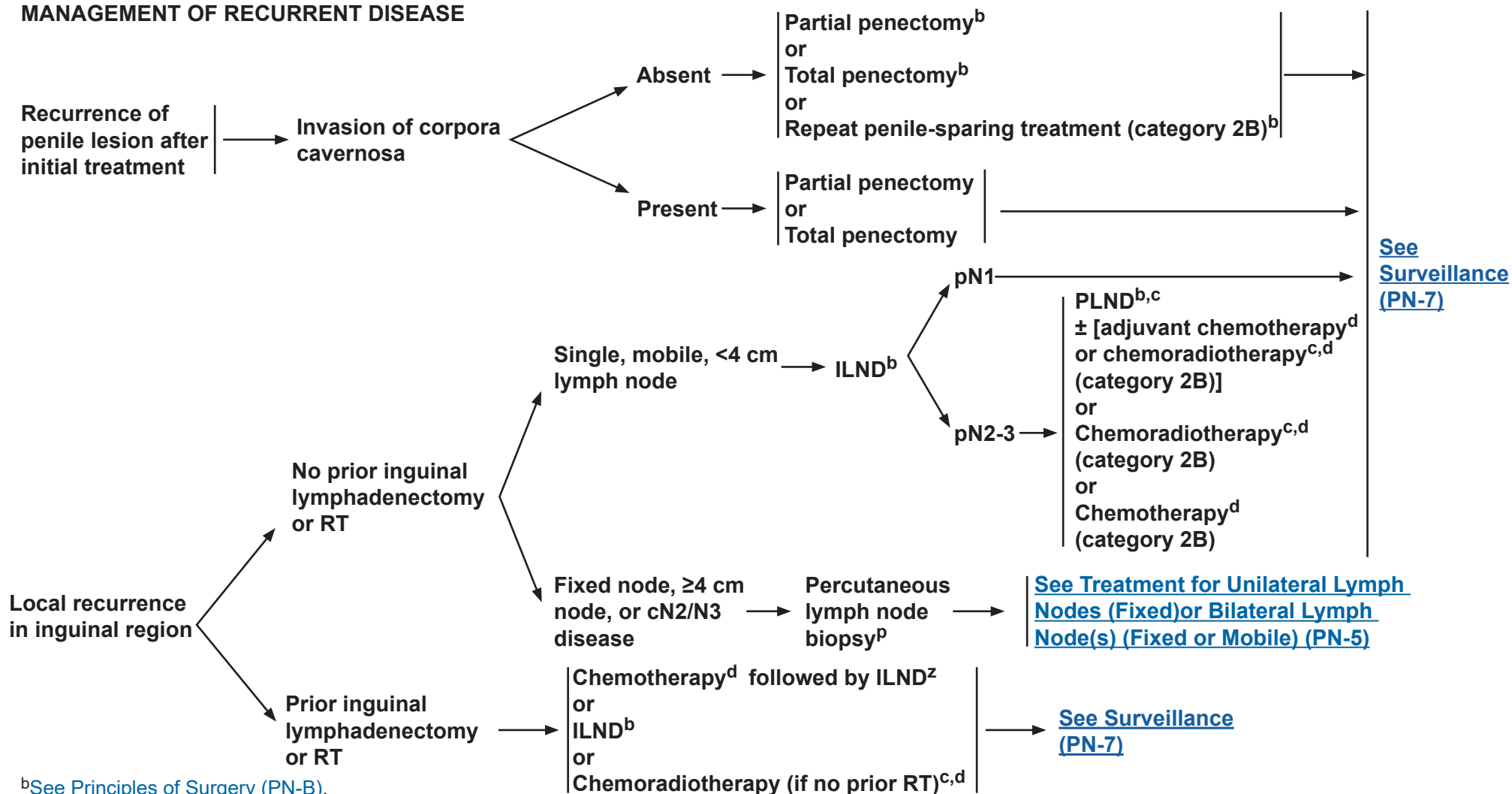
Clinical Trials: NCCN believes that the best management of any patient with cancer is in a clinical trial. Participation in clinical trials is especially encouraged.



NCCN Guidelines Version 2.2017

Penile Cancer

MANAGEMENT OF RECURRENT DISEASE



^bSee Principles of Surgery (PN-B).

^cSee Principles of Radiotherapy (PN-C).

^dSee Principles of Chemotherapy (PN-D).

^pUltrasound- or CT-guided biopsy.

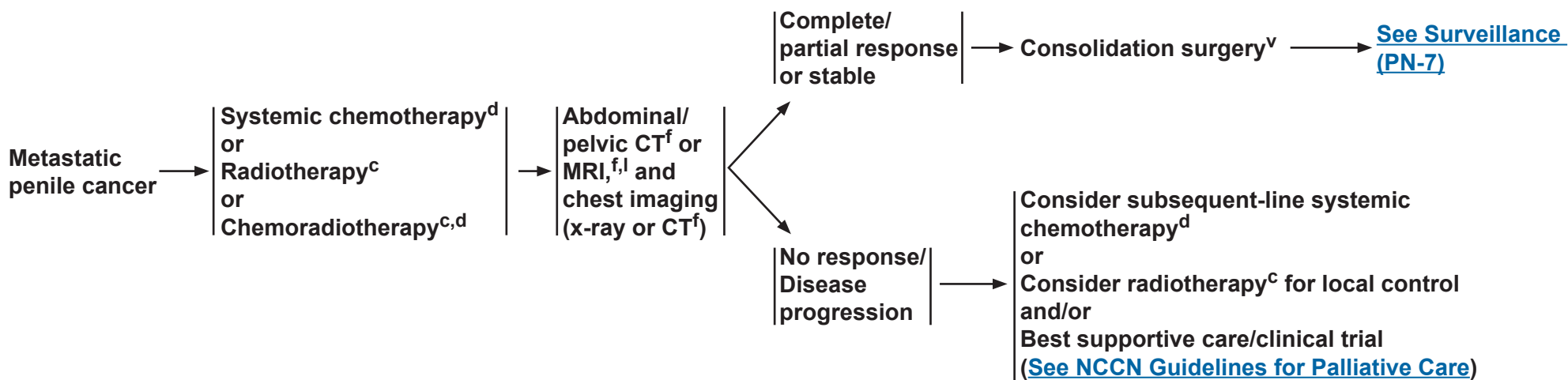
^zBaumgarten AS, Alhammali E, Hakky TS, et al. Salvage surgical resection for isolated locally recurrent inguinal lymph node metastasis of penile cancer: international study collaboration. J Urol 2014;192:760-764.

Note: All recommendations are category 2A unless otherwise indicated.

Clinical Trials: NCCN believes that the best management of any patient with cancer is in a clinical trial. Participation in clinical trials is especially encouraged.



MANAGEMENT OF METASTATIC DISEASE



^cSee [Principles of Radiotherapy \(PN-C\)](#).

^dSee [Principles of Chemotherapy \(PN-D\)](#).

^fWith contrast unless contraindicated.

^lConsider PET/CT scan.

^vConsolidation surgery consists of bilateral superficial and deep ILND and possible bilateral PLND.

Note: All recommendations are category 2A unless otherwise indicated.

Clinical Trials: NCCN believes that the best management of any patient with cancer is in a clinical trial. Participation in clinical trials is especially encouraged.



NCCN Guidelines Version 2.2017

Penile Cancer

PRINCIPLES OF PENILE ORGAN-SPARING APPROACHES

Tis, Ta, and T1 penile cancer lesions may be amenable to conservative penile organ-sparing approaches, including topical therapy, wide local excision, laser therapy, glanssectomy, and Mohs surgery.

Topical therapy¹

- For patients with Tis or Ta disease:
 - ◊ Imiquimod 5%, apply at night three times per week for 4–16 weeks.
 - ◊ 5-FU cream 5%, apply twice daily for 2–6 weeks.

Laser therapy (category 2B)

- The use of therapeutic lasers (CO₂, Nd:YAG, and KTP) to treat selected (clinical stage Tis, Ta, and T1 Grade 1-2) primary penile tumors has been reported with acceptable outcomes.
- Perioperative application of 3%–5% acetic acid to the potentially affected genital skin can be used to identify suspected sites of human papillomavirus (HPV)-infected skin that turns white upon exposure, making these acetowhite areas appropriately targetable for laser ablation.
- A plume (smoke) evacuator is recommended during penile laser treatments to minimize exposure to HPV and other viral particles as well as combustion-related carcinogens.
- The following is a table of the therapeutic lasers commonly used to treat penile cancer including suggested settings.

	<u>CO₂</u>	<u>Nd:YAG</u>	<u>KTP</u>
Type	Gas	Solid state	Solid state
Wavelength	10,600 nm	1,064 nm	532 nm
Tissue penetration	0.1 mm	3–4 mm	1–2 mm
Commonly used settings	Spot size: 3 mm Power: 5–10 W Pulse: continuous or superpulse 100–200 Hz	Spot size: 5 mm Power: 40 W Pulse duration: 1 ms Pulse frequency: 10–40 Hz	Fiber size: 400 or 600 um Power: 5–10 W Pulse duration: 10–20 ms Repetition Rate: 2 Hz

[Continued on next page](#)

¹McGillis ST1, Fein H. Topical treatment strategies for non-melanoma skin cancer and precursor lesions. Semin Cutan Med Surg 2004;23:174-183.

Note: All recommendations are category 2A unless otherwise indicated.

Clinical Trials: NCCN believes that the best management of any patient with cancer is in a clinical trial. Participation in clinical trials is especially encouraged.



NCCN Guidelines Version 2.2017

Penile Cancer

PRINCIPLES OF PENILE ORGAN-SPARING APPROACHES

Wide Local Excision

- For early-stage penile cancer confined to the skin with little or no invasion (clinical stage Tis, Ta, T1).
- The surgical margins for wide local excision depend on the location of the penile tumor.
 - ▶ Penile tumors of the shaft may be treated with wide local excision, with or without circumcision.
 - ▶ Circumcision alone may be reasonable for tumors of the distal prepuce.
- Complete excision of the skin with a wide negative margin is needed and may require the use of a split-thickness skin graft (STSG) or full-thickness skin graft (FTSG) (if a primary tension-free reapproximation cannot be completed).
- If positive surgical margins, re-resection may be considered for low-grade disease.
- Glans resurfacing may be considered in highly select patients.

Glansectomy

- Glansectomy may be considered for select patients with distal tumors (clinical stage Ta, Tis, and T1) on the glans or prepuce.
 - ▶ For patients with Ta or Tis disease, a complete glansectomy is a category 2B recommendation.
 - ▶ For patients with T1 G1-2 disease, glansectomy is not recommended unless required to ensure complete tumor eradication with negative margins.
- Negative surgical margins should be determined from frozen sections of the cavernosal bed and urethral stump.
- Treatment is followed in certain instances with a STSG or FTSG to create a neoglans.

Mohs Micrographic Surgery (category 2B)

- Mohs surgery is an alternative to wide local excision in select cases.²
 - ▶ Thin layers of cancerous skin are excised and viewed microscopically until a tissue layer is negative for the tumor.
 - ▶ Allows for increased precision, though the success rate declines with higher stage disease.
- May be preferable for a small superficial lesion on the proximal shaft to avoid total penectomy for an otherwise fairly low-risk lesion.

²Shindel AW, Mann MW, Lev RY, et al. Mohs micrographic surgery for penile cancer: management and long-term followup. J Urol 2007;178:1980-1985.

Note: All recommendations are category 2A unless otherwise indicated.

Clinical Trials: NCCN believes that the best management of any patient with cancer is in a clinical trial. Participation in clinical trials is especially encouraged.



PRINCIPLES OF SURGERY

Penectomy

- Partial penectomy should be considered the standard for high-grade primary penile tumors, provided that a functional penile stump can be preserved and negative margins are obtained. If a partial penectomy is not possible, a total penectomy should be performed.
- Partial or total penectomy when invasion into the corpora cavernosum is necessary to achieve a negative margin.
- Intraoperative frozen sections are recommended to determine negative margins.

Surgical Management of Inguinal and Pelvic Lymph Nodes

- Standard or modified ILND or DSNB is indicated in patients with penile cancer in the absence of palpable inguinal adenopathy if high-risk features for nodal metastasis are seen in the primary penile tumor:
 - ▶ Lymphovascular invasion
 - ▶ \geq pT1G3 or \geq T2, any grade
 - ▶ >50% poorly differentiated
- DSNB is only recommended if the treating physician has experience with this modality.
- If positive lymph nodes are found on DSNB, ILND is recommended.
- PLND should be considered at the time or following ILND in patients with \geq 2 positive inguinal nodes on the ipsilateral ILND site or in the presence of extranodal extension on final pathological review.
- A bilateral PLND should be considered either at the time or following ILND in patients with \geq 4 positive inguinal nodes (in total among both sides).¹
- See Discussion for further details regarding ILND and PLND.

¹Zargar-Shoshtari K, Djajadiningrat R, Sharma P, et al. Establishing criteria for bilateral pelvic lymph node dissection in the management of penile cancer: lessons learned from an international multicenter collaboration. J Urol 2015;194:696-701.

Note: All recommendations are category 2A unless otherwise indicated.

Clinical Trials: NCCN believes that the best management of any patient with cancer is in a clinical trial. Participation in clinical trials is especially encouraged.



PRINCIPLES OF RADIOTHERAPY

Primary Radiation/Chemoradiation Therapy (Penile Preservation)

T1-2, N0

If tumor <4 cm

- Circumcision followed by either:

- ▶ Brachytherapy alone^{1,2} (category 2B) (should be performed with interstitial implant);
 - or

- ▶ EBRT (category 2B): Total dose 65–70 Gy with conventional fractionation using appropriate bolus to primary penile lesion with 2-cm margins.

- ▶ EBRT with concurrent chemotherapy (category 3):³ Total dose 65–70 Gy with conventional fractionation using appropriate bolus to primary penile lesion with 2-cm margins.

- ▶ Consider prophylactic EBRT to inguinal lymph nodes in patients who are not surgical candidates or who decline surgical management.

If tumor ≥4 cm

- Circumcision followed by either:

- ▶ EBRT with concurrent chemotherapy (category 3):³ 45–50.4 Gy to a portion of or whole penile shaft depending on bulk and extent of lesion plus pelvic/inguinal nodes, then boost primary lesion with 2-cm margins (total dose 60–70 Gy);
 - or

- ▶ Brachytherapy alone (category 2B) in select cases and with careful post-treatment surveillance.

T3-4 or N+ (surgically unresectable)

- Circumcision followed by:

- ▶ EBRT with concurrent chemotherapy (category 3):³ 45–50.4 Gy to whole penile shaft, pelvic lymph nodes, and bilateral inguinal lymph nodes, then boost primary lesion with 2-cm margins and gross lymph nodes (total dose 60–70 Gy).

Primary Site Margin Positive Following Penectomy

- Postsurgical EBRT: 60–70 Gy to the primary tumor site and surgical scar (for close margins observation may be considered).

- Treat bilateral inguinal lymph nodes and pelvic lymph nodes if no or inadequate lymph node dissection.

- Brachytherapy may be considered in select cases.

Adjuvant Chemoradiotherapy

- Inguinal and/or Pelvic Lymph Node Positive

- ▶ Recommended for palpable bulky inguinal lymph nodes or enlarged pelvic lymph nodes;³ Consider for palpable non-bulky inguinal lymph nodes pN2-3 disease (category 2B) or for local recurrence to inguinal region (category 2B).

- ▶ Inguinal and pelvic lymph node EBRT to 45–50.4 Gy.

- ▶ Boost gross nodes and areas of extracapsular extension to a total dose of 60–70 Gy.

- ▶ Treat primary site of disease if positive margin.

¹Crook J, Ma C, Grimard L. World J Urol 2009;27:189-196.

²de Crevoisier R, Slimane K, Sanfilippo N, et al. Int J Radiat Oncol Biol Phys 2009;74:1150-1156.

³For potential radiosensitizing agents and combinations, see [Principles of Chemotherapy \(PN-D 2 of 2\)](#).

Note: All recommendations are category 2A unless otherwise indicated.

Clinical Trials: NCCN believes that the best management of any patient with cancer is in a clinical trial. Participation in clinical trials is especially encouraged.



PRINCIPLES OF CHEMOTHERAPY

Neoadjuvant Chemotherapy Prior to ILND or PLND

- Neoadjuvant chemotherapy with TIP (paclitaxel, ifosfamide, and cisplatin) should be considered the standard (prior to ILND) in patients with ≥ 4 cm inguinal lymph nodes (fixed or mobile), if FNA is positive for metastatic penile cancer.¹
 - ▶ Patients with initially unresectable (T4) primary tumors may be downstaged by response to chemotherapy.
- A Tx, N2-3, M0 penile cancer can receive 4 courses of neoadjuvant TIP. Stable or responding disease should then undergo consolidative surgery with curative intent. The phase II response rate was 50% in the neoadjuvant setting. The estimated rate of long-term progression-free survival for intent to treat was 36.7%. Improved progression-free and overall survival times were associated with objective response to chemotherapy.²

Adjuvant Chemotherapy Following ILND or PLND

- There are no sufficient data to form conclusions about the use of adjuvant chemotherapy. By extrapolation from the neoadjuvant data, it is reasonable to give 4 courses of TIP in the adjuvant setting if it was not given preoperatively and the pathology shows high-risk features. 5-FU plus cisplatin can be considered as an alternative to TIP in the adjuvant setting.
([See Management of Palpable Bulky Inguinal Lymph Nodes, PN-5](#)) Adjuvant EBRT or chemoradiotherapy can also be considered for patients with high-risk features.
- High-risk features include any of the following:
 - ▶ Pelvic lymph node metastases
 - ▶ Extranodal extension
 - ▶ Bilateral inguinal lymph nodes involved
 - ▶ 4-cm tumor in lymph nodes

Metastatic/Recurrent

- TIP is a reasonable first-line treatment for patients with metastatic penile cancer, including palliative treatment of patients with distant metastases.²
- 5-FU + cisplatin has been used historically for metastatic penile cancer and can be considered as an alternative to TIP.³ It appears to be effective for some patients, although the toxicities may be limiting and require dose reductions.⁴
- Bleomycin-containing regimens are associated with unacceptable toxicity⁵ and are no longer recommended.
- There are no randomized clinical trials due to the rarity of penile cancer in industrialized countries.

Subsequent-line

- No standard subsequent-line systemic therapy exists.
- A clinical trial is preferred. The evidence to support the palliative use of second-line therapy is limited.⁶ In select patients, paclitaxel⁷ or cetuximab⁸ may be considered, especially if not previously treated with a similar class of agent.

[Continued on PN-D 2 of 2](#)
[References on PN-D 2 of 2](#)

Note: All recommendations are category 2A unless otherwise indicated.

Clinical Trials: NCCN believes that the best management of any patient with cancer is in a clinical trial. Participation in clinical trials is especially encouraged.



PRINCIPLES OF CHEMOTHERAPY

Preferred combination chemotherapy regimens

TIP² (preferred)

Paclitaxel 175 mg/m² IV over 3 hours on Day 1
Ifosfamide 1200 mg/m² IV over 2 hours on Days 1–3
Cisplatin 25 mg/m² IV over 2 hours on Days 1–3
Repeat every 3 to 4 weeks

5-FU + cisplatin⁴ (not recommended for neoadjuvant setting)

Continuous infusion 5-FU 800–1000 mg/m²/d IV on Days 1–4 or Days 2–5
Cisplatin 70–80 mg/m² IV on Day 1
Repeat every 3 to 4 weeks

Radiosensitizing agents and combinations⁹ (Chemoradiotherapy)

• Preferred

► **Cisplatin alone, or in combination with 5-FU**

• Alternate options

► **Mitomycin C in combination with 5-FU**
► **Capecitabine (for palliation)**

References

- ¹Pettaway CA, Pagliaro L, Theodore C, Haas G. Treatment of visceral, unresectable, or bulky/unresectable regional metastases of penile cancer. *Urology* 2010;76:S58-65.
- ²Pagliaro LC, Williams DL, Daliani D, et al. Neoadjuvant paclitaxel, ifosfamide, and cisplatin chemotherapy for metastatic penile cancer: a phase II study. *J Clin Oncol* 2010;28:3851-3857.
- ³Hakenberg OW, Compérat EM, Minhas S, Necchi A, Protzel C, Watkin N; European Association of Urology. EAU guidelines on penile cancer: 2014 update. *Eur Urol* 2015;67:142-150.
- ⁴Di Lorenzo G, Buonerba C, Federico P, et al. Cisplatin and 5-fluorouracil in inoperable, stage IV squamous cell carcinoma of the penis. *BJU Int* 2012;110(11 Pt B):E661-6.
- ⁵Haas GP, Blumenstein BA, Gagliano RG, et al. Cisplatin, methotrexate and bleomycin for the treatment of carcinoma of the penis: a Southwest Oncology Group study. *J Urol* 1999;161:1823-1825.
- ⁶Wang J, Pettaway CA, Pagliaro LC. Treatment for metastatic penile cancer after first-line chemotherapy failure: analysis of response and survival outcomes. *Urology* 2015;85:1104-1110.
- ⁷Di Lorenzo G, Federico P, Buonerba C, et al. Paclitaxel in pretreated metastatic penile cancer: final results of a phase 2 study. *Eur Urol* 2011;60:1280-1284.
- ⁸Carthon BC, Ng CS, Pettaway CA, Pagliaro LC. Epidermal growth factor receptor-targeted therapy in locally advanced or metastatic squamous cell carcinoma of the penis. *BJU Int* 2014;113:871-877.
- ⁹Pagliaro LC, Crook J. Multimodality therapy in penile cancer: when and which treatments? *World J Urol* 2009;27:221-225.

Note: All recommendations are category 2A unless otherwise indicated.

Clinical Trials: NCCN believes that the best management of any patient with cancer is in a clinical trial. Participation in clinical trials is especially encouraged.



NCCN Guidelines Version 2.2017 Staging Penile Cancer

Table 1
**American Joint Committee on Cancer (AJCC)
TNM Staging System for Penile Cancer (7th ed., 2010)**
Primary Tumor (T)

TX	Primary tumor cannot be assessed
T0	No evidence of primary tumor
Ta	Noninvasive verrucous carcinoma*
Tis	Carcinoma in situ
T1a	Tumor invades subepithelial connective tissue without lymph vascular invasion and is not poorly differentiated (i.e., grade 3-4)
T1b	Tumor invades subepithelial connective tissue with lymph vascular invasion or is poorly differentiated
T2	Tumor invades corpus spongiosum or cavernosum
T3	Tumor invades urethra
T4	Tumor invades other adjacent structures

*Note: Broad pushing penetration (invasion) is permitted; destructive invasion is against the diagnosis

Regional Lymph Nodes (N)

Clinical Stage Definition*

cNX	Regional lymph nodes cannot be assessed
cN0	No lymph node metastasis
cN1	Palpable mobile unilateral inguinal lymph node
cN2	Palpable mobile multiple or bilateral inguinal lymph nodes
cN3	Palpable fixed inguinal nodal mass or pelvic lymphadenopathy unilateral or bilateral

Pathologic Stage Definition*

pNX	Regional lymph nodes cannot be assessed
pN0	No regional lymph node metastasis
pN1	Metastasis in a single inguinal node
pN2	Metastasis in multiple or bilateral inguinal lymph nodes
pN3	Extranodal extension of lymph node metastasis or pelvic lymph node(s) unilateral or bilateral

*Note: Pathologic stage definition based on biopsy or surgical excision.

Distant Metastasis (M)

M0	No distant metastasis
M1	Distant metastasis

Used with the permission of the American Joint Committee on Cancer (AJCC), Chicago, Illinois. The original and primary source for this information is the AJCC Cancer Staging Manual, Seventh Edition (2010) published by Springer Science+Business Media, LLC (SBM). (For complete information and data supporting the staging tables, visit www.springer.com.) Any citation or quotation of this material must be credited to the AJCC as its primary source. The inclusion of this information herein does not authorize any reuse or further distribution without the expressed, written permission of Springer SBM, on behalf of the AJCC.

ANATOMIC STAGE/PROGNOSTIC GROUPS

Stage 0	Tis	N0	M0
	Ta	N0	M0
Stage I	T1a	N0	M0
Stage II	T1b	N0	M0
	T2	N0	M0
	T3	N0	M0
Stage IIIA	T1-3	N1	M0
Stage IIIB	T1-3	N2	M0
Stage IV	T4	Any N	M0
	Any T	N3	M0
	Any T	Any N	M1



NCCN Guidelines Version 2.2017

Penile Cancer

Discussion

NCCN Categories of Evidence and Consensus

Category 1: Based upon high-level evidence, there is uniform NCCN consensus that the intervention is appropriate.

Category 2A: Based upon lower-level evidence, there is uniform NCCN consensus that the intervention is appropriate.

Category 2B: Based upon lower-level evidence, there is NCCN consensus that the intervention is appropriate.

Category 3: Based upon any level of evidence, there is major NCCN disagreement that the intervention is appropriate.

All recommendations are category 2A unless otherwise noted.

Table of Contents

Overview	MS-2
Literature Search Criteria and Guidelines Update Methodology	MS-2
Risk Factors	MS-2
Clinical Presentation	MS-3
Characterization and Clinical Staging	MS-3
Management of Primary Lesions	MS-4
Diagnosis	MS-4
Penile Organ-Sparing Approaches	MS-4
NCCN Recommendations	MS-6
Management of Regional Lymph Nodes	MS-7

Evaluation and Risk Stratification	MS-7
Dynamic Sentinel Node Biopsy	MS-8
Inguinal Lymph Node Dissection	MS-9
Modified Template Lymphadenectomy	MS-10
Delayed Inguinal Lymphadenectomy	MS-10
Unilateral Versus Bilateral Lymphadenectomy	MS-10
Pelvic Lymphadenectomy	MS-10
Chemotherapy	MS-11
Chemoradiotherapy	MS-12
NCCN Recommendations	MS-12

Surveillance	MS-13
Recurrence	MS-14
Metastatic Disease	MS-14
Summary	MS-15
References	MS-16



NCCN Guidelines Version 2.2017

Penile Cancer

Overview

Squamous cell carcinoma (SCC) of the penis is a rare disease, representing 0.4% to 0.6% of all malignant neoplasms among men in the United States and Europe.¹ In 2017, the estimated number of new cases of penile and other male genital cancers in the United States is 2120, with 360 predicted cancer-specific deaths.² Incidence is higher (up to 10%) among men in the developing countries of Asia, Africa, and South America.³ The most common age of presentation is between 50 and 70 years.⁴ Early diagnosis is of utmost importance, as this is a disease that can result in devastating disfigurement and has a 5-year survival rate of approximately 50% (over 85% for patients with negative lymph nodes and 29%–40% for patients with positive nodes, with the lowest survival rates at 0% for patients with pelvic lymph node [PLN] involvement).⁵ As the rarity of this disease makes it difficult to perform prospective, randomized trials, the NCCN Panel relied on the experience of penile cancer experts and the best currently available evidence-based data to collectively lay down a foundation to help standardize the management of this malignancy.

Literature Search Criteria and Guidelines Update Methodology

Prior to the update of this version of the NCCN Guidelines for Penile Cancer, an electronic search of the PubMed database was performed to obtain key literature published between September 8, 2015 and September 8, 2016, using the following search term: penile cancer or squamous cell carcinoma of the penis. The PubMed database was chosen as it remains the most widely used resource for medical literature and indexes only peer-reviewed biomedical literature.⁶

The search results were narrowed by selecting studies in humans published in English. Results were confined to the following article

types: Clinical Trial; Guideline; Meta-Analysis; Randomized Controlled Trial; Systematic Reviews; and Validation Studies.

The PubMed search resulted in 7 citations and their potential relevance was examined. The data from key PubMed articles as well as articles from additional sources deemed as relevant to these guidelines and discussed by the panel have been included in this version of the Discussion section (eg, e-publications ahead of print, meeting abstracts). Recommendations for which high-level evidence is lacking are based on the panel's review of lower-level evidence and expert opinion.

The complete details of the Development and Update of the NCCN Guidelines are available on the NCCN [webpage](#).

Risk Factors

In the United States the median age of diagnosis is 68 years, with an increase in risk for males older than 50 years.⁷ Early detection is assisted by the ability to do a good physical exam. Phimosis may hinder the capability to properly inspect the areas of highest incidence—the glans, inner preputial layer, coronal sulcus, and shaft. Men with phimosis carry an increased risk for penile cancer of 25% to 60%.^{4,8,9} A review of penile SCC in the United States showed that 34.5% of patients had the primary lesion on the glans, 13.2% on the prepuce, and 5.3% on the shaft, with 4.5% overlapping and 42.5% unspecified.⁷ Other risk factors include balanitis, chronic inflammation, penile trauma, lack of neonatal circumcision, tobacco use, lichen sclerosus, poor hygiene, and a history of sexually transmitted disease(s), especially HIV and HPV.⁴ Overall, about 45% to 80% of penile cancers are related to HPV, with a strong correlation with types 16 and 18.^{4,8,10,11} There is an 8-fold increased risk for patients with HIV, which may correspond to a higher incidence of HPV among males with HIV.¹² Neonatal



NCCN Guidelines Version 2.2017

Penile Cancer

circumcision is associated with a lower rate of penile cancer, though the protective effect is not seen in adults who have the foreskin removed. This reduced incidence of penile cancer in patients who have been circumcised in infancy may reflect other known risk factors including the elimination of phimosis and lower incidence and duration of HPV infections in this population (reviewed by Morris et al¹³). A small study suggests that the benefits of circumcision may reduce invasive penile cancer but not carcinoma in situ (CIS, also called TIS).¹⁴ Cigarette smokers are noted to be 3 to 4.5 times more likely to develop penile cancer.^{10,15} Patients with lichen sclerosus have a 2% to 9% risk of developing penile carcinoma.¹⁶⁻¹⁸ Psoriasis patients undergoing psoralen plus ultraviolet A (PUVA) treatment have an increased penile cancer incidence of 286 times compared to the general population. Therefore, they should be shielded during treatment and any penile lesion should be closely monitored.¹⁹ A study of men with advanced penile SCC receiving systemic therapy identified visceral metastases and an ECOG performance score greater than or equal to 1 as poor prognostic factors for both overall survival (OS) and progression-free survival.²⁰ However, studies remain limited on predictive factors of prognosis in this patient population.

Clinical Presentation

Most often penile SCC presents as a palpable, visible lesion on the penis, which may be associated with penile pain, discharge, bleeding, or a foul odor if the patient delays seeking medical treatment. The lesion may be characterized as nodular, ulcerative, or fungating, and may be obscured by phimosis. The patient may exhibit signs of more advanced disease, including palpable nodes and/or constitutional symptoms (eg, fatigue, weight loss).

Characterization and Clinical Staging

Approximately 95% of penile cancers originate in squamous epithelial cells and are further categorized as either SCC or penile intraepithelial neoplasia (PIN).²¹ PIN is a premalignant condition at high risk of developing into SCC of the penis and includes the clinical entities of bowenoid papulosis, erythroplasia of Queyrat, and Bowen's disease.²¹ The AJCC recognizes four subtypes of SCC: verrucous, papillary squamous, warty, and basaloid.²² The verrucous subtype is considered to demonstrate low malignant potential, while other variants reported—adenosquamous and sarcomatoid variants—carry a worse prognosis.^{23,24} The primary lesion is further characterized by its growth pattern with superficial spread, nodular or vertical-phase growth, and verrucous pattern. In addition to the penile lesion, evaluation of lymph nodes is also critical, as involvement of the inguinal lymph nodes (ILNs), the number and site of positive nodes, and extracapsular nodal involvement provide the strongest prognostic factors of survival.^{5,25}

The AJCC Tumor, Node, and Metastasis (TNM) system for penile carcinoma has been used for staging, with the most recent update published in 2010. It was initially introduced in 1968 and was subsequently revised in 1978, 1987, and 2002.^{22,26-29} In 2010, the AJCC made the distinction between clinical and pathologic staging while eliminating the difference between superficial and deep inguinal metastatic nodes.²² Other changes included subdivision of T1 into T1a and T1b as determined by the presence or absence of lymphovascular invasion or poorly differentiated cancers; limitation of the T3 category to urethral invasion and T4 to prostatic invasion; and grouping of stage II to include T1b N0M0 as well as T2-3 N0M0 (see *Staging* in the algorithm). A grading system for SCC of the penis based on degree of cell anaplasia is defined as: grade 1, well differentiated (no evidence of anaplasia); grade 2, moderately differentiated (<50% anaplasia); and



NCCN Guidelines Version 2.2017

Penile Cancer

grade 3, poorly differentiated (>50% anaplastic cells).³⁰ According to the AJCC, if no grading system is specified, a general system should be followed: GX, grade cannot be assessed; G1-3 as previously mentioned above; and G4, undifferentiated.²² The overall degree of cellular differentiation with high-risk, poorly differentiated tumors is an important predictive factor for metastatic nodal involvement.³¹ The AJCC also recommends collection of site-specific factors, including: the distinction between corpus spongiosum and corpus cavernosum involvement, the percentage of tumor that is poorly differentiated, the depth of invasion in verrucous carcinoma, the size of the largest lymph node metastasis, and HPV status.²²

Management of Primary Lesions

Diagnosis

Evaluation of the primary lesion, regional lymph nodes, and distant metastasis will dictate the appropriate and adequate management of SCC of the penis, beginning with the first evaluation at presentation and then throughout follow-up. Vital to the initial management is a good physical exam of the penile lesion(s) that remarks on the diameter of the lesion(s) or suspicious areas; location(s) on the penis; number of lesions; morphology of the lesion(s); whether the lesion(s) are papillary, nodular, ulcerous, or flat; and relationship with other structures including submucosal, urethra, corpora spongiosa, and/or corpora cavernosa. To complete the initial evaluation, a histologic diagnosis with a punch, excisional, or incisional biopsy is paramount in determining the treatment algorithm based on a pathologic diagnosis.^{22,32,33} This will provide information on the grade of the tumor, and will assist in the risk stratification of the patient for regional lymph node involvement.^{32,33} MRI or ultrasound can be used to evaluate the depth of tumor invasion.³⁴ An ultrasound may also be considered for evaluation of ILNs that are

difficult to assess. For the evaluation of lymph nodes, see *Management of Regional Lymph Nodes*.

Penile Organ-Sparing Approaches

Tis, Ta, and T1 penile cancer lesions may be amenable to conservative penile organ-sparing approaches, including topical therapy, laser therapy, wide local excision, glansctomy, and Mohs surgery. Careful consideration should be given to penile-preserving techniques if the patient is reliable in terms of compliance with close follow-up.

Topical Therapy

Topical therapy is a valuable outpatient treatment due to ease of administration; however, patients should be monitored for adherence to therapy and for toxicity or adverse events. Local skin and application site reactions may occur and are generally mild to moderate, though severe reactions may occur with a higher frequency of application. Modification of the application frequency can resolve these complications. Despite significant response rates, the probability of relapse is higher following topical therapy than with other more aggressive therapies. Therefore, patients who are eligible for topical therapy should be routinely monitored for recurrence.

While topical therapy for the treatment of PIN has been reported in numerous case studies and case reports, the data are limited by the small sample sizes and variation in treatment protocols. A retrospective review from a prospective database of patients diagnosed with PIN over a 10-year range identified patients who received either 5-fluorouracil (5-FU) as first-line therapy or imiquimod as the second-line topical agent.³⁵ Topical chemotherapy was given to 45 patients with a mean follow-up of 34 months. Therapy was standardized to 12 hours every 48 hours for 28 days. A complete response (CR) was reported in 25 patients (57%), while a partial response was seen in 6 patients (13.6%);



NCCN Guidelines Version 2.2017

Penile Cancer

no response was observed in the remaining 13 patients (29.5%). Following application of 5-FU, local toxicity and adverse events occurred in 10% and 12% of patients, respectively.³⁵ In another study, 5-FU treatment duration ranged from 3 to 7 weeks and was determined based on clinical response.³⁶ Out of 19 patients, 14 (73.7%) had a CR and none of the patients had recurrence at the median time of follow-up (3.5 years).³⁶ Topical 5-FU for 6 weeks has also reported good response rates at 5 years.^{37,38}

Imiquimod has been investigated as a second-line therapy for PIN. Due to its ability to produce significant inflammation, initiation of imiquimod therapy at a lower frequency (eg, 2 times per week) may be beneficial to evaluate for toxicity or adverse events before increasing the frequency of application. Early studies suggested a 100% response to imiquimod (n = 47; 70% CR)³⁹, though a subsequent review identified a lower response to therapy with 63% of patients showing a CR and 29% of patients showing no response.⁴⁰ The study highlighted that the difference in response may be related to the frequency and duration of application as well as the PIN subtype. In this study, bowenoid papulosis and Bowen's disease subtypes responded better to imiquimod than the erythroplasia of Queyrat subtype. Longer, less frequent application (ie, fewer than 4 times per week for an average of 113 days) was demonstrated to have a better response than a shorter, more frequent application (ie, 4 times or more per week for an average of 53 days) (81% vs. 68%, respectively).

Laser Therapy

Laser therapy in select patients with Tis, Ta, or T1 G1-2 penile cancer has reported acceptable outcomes (see *Principles of Penile Organ-Sparing Approaches* in the algorithm). Four types of therapeutic lasers have been used and include carbon dioxide, Nd:YAG, argon, and KTP lasers. Nd:YAG and carbon dioxide lasers are the most commonly

used, though KTP laser may also be considered. Nd:YAG lasers have the deepest penetration capability of 3 to 4 mm compared with the carbon dioxide laser that penetrates to a depth of 0.1 mm and KTP lasers that penetrate to 1 to 2 mm.

Retrospective studies of laser therapy reported local recurrence rates of around 18%, comparable to that of surgery, with good cosmetic and functional results.^{41,42} Penoscopically controlled laser excision of TIS or T1 penile carcinoma in 224 patients compared outcomes based on primary treatment with excisional surgery for CIS or initially invasive flat tumors.⁴³ Reductive chemotherapy was given prior to surgery for exophytic lesions to broaden the indication of laser excision. Complete excision with adequate lateral margins was achieved in 221 patients and with adequate deep margins in 217 patients. The 10-year recurrence rate was 17.5% (95% CI, 16.4%–18.6%), and the 10-year amputation rate was 5.5% (range, 5.2%–5.7%).⁴³ In a subsequent study from this group, 56 patients with pT1 disease were treated with carbon dioxide laser therapy. There were 53 patients alive and disease free at a median follow-up of 66 months.⁴⁴ The three deaths in the study were the result of unrelated and intercurrent disease. Among the 53 patients evaluated at follow-up, 13 had local recurrence and 2 had positive ILNs. The local recurrence correlated to positive margins.⁴⁴ Another study evaluated Nd:YAG laser treatment of patients with T1, T2 or CIS disease. Local recurrence was reported in 48% of patients, with recurrence elsewhere in the glans penis occurring in 20% of cases.⁴⁵ There were 10 cases of nodal metastases, of which 8 were in patients with T2 disease.⁴⁵ These data emphasize the greater benefit of laser therapy in CIS or T1 disease.

Glansectomy

Glansectomy, removal of the glans penis, may be considered for patients with distal tumors (clinical stage Ta, Tis, T1) on the glans or



NCCN Guidelines Version 2.2017

Penile Cancer

prepuce. Negative surgical margins should be determined from frozen sections of the cavernosal bed and urethral stump. Treatment in certain instances may include a split- or full-thickness skin graft.

A recent retrospective study of 177 patients with SCC of the glans who received glansectomy and split-thickness skin graft had a 9.3% incidence of local recurrence (median follow-up, 41.4 months).⁴⁶ In total, 13 patients received treatment for operative complications and 18 patients (10.7%) died from penile cancer. An earlier retrospective study including 25 patients demonstrated a disease-specific survival of 92%.⁴⁷ Taken together, studies indicate a low level of recurrence.⁴⁷⁻⁵⁰

Wide Local Excision

For wide local excision, a complete excision of the skin with a wide negative margin with skin grafting is needed. Surgical margins depend on the location of the tumor. Penile tumors of the shaft may be treated with wide local excision, with or without circumcision. Circumcision alone may be reasonable for tumors of the distal prepuce. Either a split-thickness skin graft or full-thickness skin graft may be considered. Emphasis is placed again on patient selection and close follow-up, as the 2-year recurrence rate may reach up to 50%.⁵¹ Studies have shown that surgical margins of 5 to 10 mm are as safe as 2-cm surgical margins, and 10- to 20-mm margins provide adequate tumor control.⁵²

Mohs Surgery

Mohs surgery is an alternative to wide local excision in select patients.⁵³ This technique removes thin layers of cancerous skin, which are evaluated microscopically until the tissue is negative for tumor. A retrospective study including 33 patients with SCC of the penis, ranging from T1S to T3 disease, reported outcomes for patients who were treated with Mohs surgery.⁵⁴ Follow-up data were available for 25 patients, of which 8 had local recurrence. Seven patients underwent

repeat Mohs surgery while one patient received a penectomy. One patient in this study died of metastatic disease. Although precision is higher with Mohs surgery, the success rate declines with higher stage disease. Therefore, Mohs surgery may have the greatest benefit for patients with a small superficial lesion on the proximal shaft to avoid penectomy for an otherwise fairly low-risk lesion.

NCCN Recommendations

Tis or Ta

For patients with penile CIS or noninvasive verrucous carcinoma, penis-preserving techniques may be utilized, including topical imiquimod (5%) or 5-FU cream, circumcision and wide local excision, laser therapy (category 2B), complete glansectomy (category 2B), or Mohs surgery in select cases (category 2B). Among these, topical therapy⁵⁵⁻⁵⁷ and excisional organ-sparing surgery⁵⁸ are the most widely used.

For topical therapy, NCCN recommends application of imiquimod 5% cream at night 3 times per week for 4 to 16 weeks. Topical 5% 5-FU cream should be applied twice daily for 2 to 6 weeks. Laser therapy for the treatment of primary penile tumors has demonstrated acceptable outcomes with a perioperative application between 3% and 5% acetic acid. Following application of acetic acid to the affected genital skin, suspected sites of HPV-infected skin will turn white and can be targeted for laser ablation. Gas and solid-state lasers may be considered (see *Principles of Surgery* in the algorithm).

T1G1-2

Careful consideration should be given to penile-preserving techniques if the patient is reliable in terms of compliance with close follow-up. These techniques include wide local excision,⁵³ glansectomy in select cases,



Mohs surgery in select cases (category 2B), laser therapy (category 2B),⁵⁹ and radiotherapy (category 2B) delivered as brachytherapy with interstitial implant (preferred) or external beam radiation therapy (EBRT).⁶⁰⁻⁶⁴ Circumcision should always precede radiation therapy (RT) to prevent radiation-related complications.

T1G3-4 or T≥2

These lesions typically require more extensive surgical intervention with partial or total penectomy depending on the characteristics of the tumor and depth of invasion.^{32,33} Intraoperative frozen sectioning is recommended to achieve negative surgical margins. If the tumor encompasses less than half of the glans and the patient agrees to very close observation, then a more conservative approach such as wide local excision or glansectomy may be considered for patients with T1G3-4 diagnosis. The patient should understand that there is an increased risk for recurrence and potential for a repeat wide local excision should a local recurrence be noted, provided there is no invasion of the corpora cavernosa.^{42,50} A clear and frank discussion should be had with the patient that a partial or total penectomy will likely be required should a larger or more invasive lesion be present.

The tumor size is an important factor when choosing RT as treatment. As the average length of the glans is about 4 cm, this serves as a cutpoint to reduce the risk of under-treating cavernosal lesions. In a study of 144 patients with penile cancer restricted to the glans treated by brachytherapy, larger tumors, especially those larger than 4 cm, are associated with higher risk of recurrence.⁶⁵ A high, 10-year, cancer-specific survival rate of 92% was achieved in this series.

There was nonuniform consensus among NCCN panelists on the use of RT as primary therapy due to scant data. For T1G3-4 or T2 tumors smaller than 4 cm with negative nodes, brachytherapy with interstitial

implant, EBRT alone (category 2B), or EBRT with chemotherapy (category 3) are treatment options after circumcision. Consider prophylactic ILN irradiation if selecting EBRT.

For tumors 4 cm or larger or if there is node-positive disease that is surgically unresectable, circumcision should be performed followed by EBRT combined with chemotherapy. Brachytherapy following circumcision may be appropriate in select cases of tumors 4 cm or larger, but careful monitoring is necessary as the risks of complications and failures increase.⁶⁶ Crook and colleagues reported a 10-year cause-specific survival of 84% in 67 patients with T1-2 (select cases of T3) penile lesions treated with primary brachytherapy.⁶⁴ Brachytherapy is not recommended following penectomy or partial penectomy but may be considered following wide local excision or excisional biopsy of small lesions. Brachytherapy should only be performed in centers with significant experience using this treatment modality.

Post-surgical RT to the primary tumor site may be considered for positive margins.

Management of Regional Lymph Nodes

Evaluation and Risk Stratification

The presence and extent of regional ILN metastases has been identified as the single most important prognostic indicator in determining long-term survival in men with invasive penile SCC.²⁵ Evaluation of the groin and pelvis is an essential component of the metastatic workup of a patient. The involvement of the ILN can be clinically evident (ie, palpable vs. non-palpable), adding to the difficulty in management. Clinical exam for ILN involvement should attempt to evaluate and assess for palpability, number of inguinal masses, unilateral or bilateral localization, dimensions, mobility or fixation of



NCCN Guidelines Version 2.2017

Penile Cancer

nodes or masses, relationship to other structures (eg, skin, Cooper's ligaments), and edema of the penis, scrotum, and/or legs.^{67,68}

Crossover drainage from left to right and vice versa does occur and is reproducible with lymphoscintigraphy.^{5,69} The physical exam should describe the diameter of node(s) or mass(es), unilateral or bilateral localization, number of nodes identified in each inguinal region, and the relationship to other structures, particularly with respect to the mobility or fixation of the node(s) or mass(es) to adjacent structures and/or involvement of the overlying skin. Imaging for palpable disease by CT or MRI may be used to assess the size, extent, location, and structures that are in close proximity to the ILN, as well as the presence of pelvic and retroperitoneal lymph nodes and distant metastasis. CT and MRI are limited in patients with non-palpable disease.^{67,70} While studies have looked at the use of nanoparticle-enhanced MRI, PET/CT, and 18F-fluorodeoxyglucose (FDG) PET/CT, the small sample sizes require validation in larger prospective studies.⁷¹⁻⁷⁴ When considering one imaging modality to evaluate the stage of the primary lesion and lymph node status, MRI appears to be the best choice to enhance the physical exam in patients where the inguinal region is difficult to assess (eg, morbidity, previous chemotherapy/radiotherapy).^{71,75}

Consideration needs to be given to whether or not the primary lesion demonstrated any adverse prognostic factors. If one or more of these high-risk features is present, then pathologic ILN staging must be performed. Up to 25% of patients with non-palpable lymph nodes harbor micrometastases.³⁰ Therefore, several predictive factors have been evaluated for their ability to identify the presence of occult lymph node metastasis.^{51,76} Slaton et al³⁰ concluded that patients with pathologic stage T2 or greater disease were at significant risk (42%–80%) of nodal metastases if they exhibited greater than 50% poorly differentiated cancer and/or vascular invasion, and therefore should be recommended

to undergo an inguinal lymph node dissection (ILND).^{5,30} These factors can then further define patients into low-, intermediate-, and high-risk groups for lymph node metastasis.^{23,77,78} The European Association of Urology determined risk stratification groups for patients with non-palpable ILNs, and validated this in both uni- and multivariate analyses of prognostic factors. Patients can be stratified based on stage and/or grade into risk groups based on the likelihood of harboring occult node-positive disease, with the low-risk group defined as patients with Tis, Ta, or T1a disease; the intermediate group as those with T1b disease (lymphovascular invasion); and the high-risk group as those with T2 or G3/G4 disease.^{68,77}

There is a paucity of data regarding the predictive value of lymph node removal. A singular study suggests that disease-specific survival following radical lymphadenectomy can be predicted by the lymph node count and lymph node density.⁷⁹ Removal of greater than or equal to 16 lymph nodes in patients with pathologic negative nodes was associated with a significantly longer disease-specific survival rate ($P < .05$). Furthermore, the 5-year disease-free survival in patients with pathologic positive nodes was 81.2% in patients with lymph node density (defined as the number of positive nodes divided by the total number of lymph nodes removed) greater than 16% compared to 24.4% in patients with less than 16% lymph node density ($P < .001$).⁷⁹ Although this study suggests that lymph node count and density may be useful in predicting disease-specific survival, a larger validation study is necessary to support these preliminary data.

Dynamic Sentinel Node Biopsy

The work by Cabanas used lymphangiograms and anatomic dissections to evaluate the sentinel lymph node drainage for penile cancer with non-palpable ILNs.⁸⁰ This technique has been shown to have



NCCN Guidelines Version 2.2017

Penile Cancer

false-negative rates as high as 25%; therefore, it is no longer recommended.^{68,81} Advancements have been made with the dynamic sentinel node biopsy (DSNB) technique developed for penile cancer by the Netherlands Cancer Institute using lymphoscintigraphy and performed with technetium-99m–labeled nanocolloid and patent blue dye isosulfan blue.^{82,83} Initially, this technique was associated with a low sensitivity and high false-negative rate (16%–43%).^{84–87} Refinement of the technique to include serial sectioning and immunohistochemical staining of pathologic specimens, preoperative ultrasonography with and without fine-needle aspiration (FNA) cytology, and exploration of groins in which no sentinel node is visualized on intraoperative assessment decreased the false-negative rate from 19% to only 5%.^{82,88} Using FNA with ultrasound can increase the diagnostic yield in metastases greater than 2 mm in diameter.^{70,89} Crashaw et al⁹⁰ used ultrasound with DSNB and noted improved accuracy in identifying patients with occult lymph node metastases. With modification of the NCI protocol, Hadway et al⁹¹ were able to achieve a similar false-negative rate (5%) with an 11-month follow-up. A recent observational cohort study of 1000 patients treated between 1956 and 2012 suggests that DSNB can improve 5-year survival in patients with clinically node-negative groins.⁹² Data in this study showed that patients treated prior to 1994 (the year DSNB was incorporated into treatment) had an 82% 5-year survival compared to the 91% 5-year survival seen in patients treated between 1994 and 2012 ($P = .021$). However, there are several limitations of this study including the possibility that improved staging resulted in more patients being grouped in a higher risk group. Therefore, incorporation of DSNB into treatment should be limited to centers with experience. Secondary to the technical challenges associated with DSNB, to be accurate and reliable, it is recommended that DSNB be performed at tertiary care referral centers

where at least 20 procedures are done per year.^{82,93} It should be noted that DSNB is not recommended in patients with palpable ILNs.⁶⁷

Inguinal Lymph Node Dissection

The most frequent sites of metastasis from penile cancer are the ILNs, typically presenting as palpable inguinal lymphadenopathy. The management of ILNs by ILND has been fraught with concerns of surgical morbidity.^{68,94} Early treatment of lymph node involvement has been shown to have a positive impact on survival, except if the patient has bulky nodal spread or other sites of metastases.^{95,96} Palpable lymphadenopathy at the time of diagnosis does not warrant an immediate ILND. Of the patients with palpable disease, 30% to 50% will be secondary to inflammatory lymph node swelling instead of metastatic disease.⁷⁶ Although the distinction between reactive lymph nodes and metastatic disease has traditionally been done with a 6-week course of antibiotics, percutaneous lymph node biopsy is the favored approach among penile cancer experts for patients with palpable nodes.^{5,67} An antibiotic course may still be used but is limited to the setting of an overlying infection.^{5,67,97}

The boundaries of the standard, full-template ILND (ie, Daseler's quadrilateral area) are: superiorly, the inguinal ligament; inferiorly, the fossa ovalis; laterally, the medical border of sartorius muscle; and medially, the lateral edge of adductor longus muscle.⁹⁷ Historically, it has been recommended to keep the patient on bed rest for 48 to 72 hours, especially after myocutaneous flaps or repair of large skin defects, although the necessity for this is debatable and not corroborated with rigorous scientific data. Closed suction drains are placed at surgery and are typically removed when drainage is less than 50 to 100 mL per day.^{97,98} Consideration should be given to keeping the patient on a suppressive dose of an oral cephalosporin (or other



NCCN Guidelines Version 2.2017

Penile Cancer

gram-positive, broad-spectrum antibiotic) for several days to weeks postoperatively in an attempt to decrease the risk of wound-related issues and minimize the risk for overall complications. However, the data supporting this treatment approach are very limited.⁹⁷

Modified Template Lymphadenectomy

In attempts to decrease the morbidity associated with standard ILND, a modified template lymphadenectomy has been proposed that uses a shorter skin incision, limiting the field of inguinal dissection by excluding the area lateral to the femoral artery and caudal to the fossa ovalis, with preservation of the saphenous vein and elimination of the need to transpose the sartorius muscle while providing an adequate therapeutic effect. This technique is commonly reserved for patients with a primary tumor that places them at increased risk for inguinal metastasis but with clinically negative groins on examination.^{97,99} The modified technique has shown a decrease in complications. Contemporary modified ILND should include the central and superior zones of the inguinal region, as these sections were not included in the dissection leading to a false-negative rate of 15%.^{100,101} It is important to note that if nodal involvement is detected on frozen section, the surgical procedure should be converted to a standard, full-template lymphadenectomy. A standard full-template lymphadenectomy should be considered in all patients who have resectable inguinal lymphadenopathy. However, studies would favor neoadjuvant chemotherapy prior to proceeding with surgery, particularly in patients with bulky ILN metastases (ie, fixed nodes or nodal diameter ≥ 3 cm).^{102,103} Generally, ILND is performed within 4 to 6 weeks following the completion of systemic chemotherapy to allow patient recovery while minimizing the risk of cancer progression post-chemotherapy.

Delayed Inguinal Lymphadenectomy

Since data exist that suggest men with clinically negative groins undergoing immediate ILND have better survival outcomes than men undergoing delayed ILND once their groins are clinically positive, it is recommended that in most circumstances men with high-risk penile tumors should undergo immediate ILND. However, patients with lower-risk tumors who are undergoing active surveillance or high-risk men who refuse immediate ILND may experience an inguinal nodal recurrence at some time point during follow-up. The median time to inguinal recurrence after treatment of the primary penile tumor is approximately 6 months, with 90% occurring by year 3 and 100% by year 5.¹⁰⁴⁻¹⁰⁶

Unilateral Versus Bilateral Lymphadenectomy

In patients with high-risk features who do not have palpable lymph nodes, bilateral lymphadenectomy is generally performed, because it is not possible to predict the laterality of inguinal nodal metastasis based on the location of the tumor on the penis. Similarly, in patients who have a unilateral palpable node, about 30% will have contralateral positive nodes that are not palpable.¹⁰⁷ Therefore, bilateral lymphadenectomy should be considered the standard of care in patients undergoing immediate ILND for high-risk penile tumors or because of palpable nodes. When there is a delayed (>1 year after treatment of the primary penile tumor) inguinal recurrence of cancer, it is usually unilateral, and some authors have suggested that ipsilateral ILND is adequate while others have advocated for bilateral ILND in this circumstance.⁵

Pelvic Lymphadenectomy

Approximately 20% to 30% of patients with positive ILNs will also have cancer within PLNs. Interestingly, penile tumors do not appear to metastasize to the PLNs without first affecting the inguinal node echelon



NCCN Guidelines Version 2.2017

Penile Cancer

(ie, no skip lesions).^{80,106} Patients who have only one positive inguinal node have a risk of pelvic nodal involvement of less than 5% as reported by the Netherlands Cancer Institute.¹⁰⁸ The presence of cancer within the PLN is associated with a very poor 5-year survival rate that is typically of less than 10%. Based on these prior reports, pelvic lymphadenectomy (resection of external iliac, internal iliac, and obturator lymph nodes) is recommended in patients with 2 or more positive ILNs and in the clinical context of high-grade cancer within the ILN pathologic specimen. Pelvic lymph node dissection (PLND) can be conducted during the same operative session as the ILND if the intraoperative frozen section is positive in 2 or more of the inguinal nodes (raising the importance of obtaining a lymph node count intraoperatively) or in a delayed staged fashion based on the pathologic features of the ILND specimen.^{109,110}

A recent retrospective analysis evaluated the benefit of adjuvant chemotherapy on OS of patients with positive PLN following lymph node dissection. Less than half of the patients in this multi-institutional study received adjuvant chemotherapy (36 out of 84). These patients were younger, had a less aggressive pathology, were less inclined to receive adjuvant radiation, and demonstrated less bilateral inguinal disease and more inguinal extranodal extension. The median OS was higher for these patients compared to patients who did not receive adjuvant chemotherapy (21.7 months vs. 10.1 months; $P = .021$). Adjuvant chemotherapy was further shown to be an independent factor in the improved OS based on multivariate analysis (HR, 0.40; 95% CI, 0.19–0.87; $P = .021$). Therefore, patients with positive PLN following surgical resection may benefit from adjuvant systemic chemotherapy.¹¹¹

One area of controversy is whether the PLND should be performed ipsilaterally or bilaterally in patients with unilateral positive ILNs. Data suggest that the number of positive ILNs identified at the time of

dissection may direct clinicians to unilateral or bilateral dissection. In a single retrospective study, the presence of 4 or more positive ILNs supported bilateral PLND.¹⁰⁶ Unilateral PLND was recommended if 3 or fewer ILN metastases were identified and if there was no suspicion of contralateral pelvic lymphadenopathy on preoperative imaging or intraoperatively. Crossover (right to left or left to right) of inguinal to pelvic nodes has not been well studied; hence, both approaches are feasible and left at the discretion of the surgeon based on case-specific characteristics.

Chemotherapy

A patient who presents with resectable bulky disease will rarely be cured with a single treatment modality. Consideration should be given to neoadjuvant chemotherapy if ILNs are greater than or equal to 4 cm. Patients who may benefit from surgical consolidation would be those who had stable, partial, or CR following systemic chemotherapy, thus increasing their potential for disease-free survival.^{102,103} Pagliaro et al¹¹² performed a phase II clinical trial in 30 patients, with stage N2 or N3 (stage III or stage IV) penile cancer without distant metastases, receiving neoadjuvant chemotherapy with paclitaxel, ifosfamide, and cisplatin. In this series, 50% of patients were noted to have a clinically meaningful response, and 22 patients (73.3%) subsequently underwent surgery. There was an improved time to progression and OS associated with chemotherapy responsiveness ($P < .001$ and $P = .001$, respectively), absence of bilateral residual tumor ($P = .002$ and $P = .017$, respectively), and absence of extranodal extension ($P = .001$ and $P = .004$, respectively) or skin involvement ($P = .009$ and $P = .012$, respectively).



NCCN Guidelines Version 2.2017

Penile Cancer

Chemoradiotherapy

Chemoradiotherapy has demonstrated improved responses in patients with other SCCs, specifically patients with vulvar and anal cancer.¹¹³⁻¹¹⁶ Anecdotal data for the use of chemoradiotherapy in patients with penile cancer have been reported with mixed results.¹¹⁷⁻¹²⁰ Based on the limited data, chemoradiotherapy is a treatment option in select patients.

For patients with T1 or T2 disease, EBRT with concurrent chemotherapy may be considered though brachytherapy is preferred for tumors less than 4 cm. Similarly, EBRT with concurrent chemotherapy can be used for T3 or T4 disease or in patients with nodal involvement. Postoperative adjuvant chemotherapy is recommended in ILN-positive patients. Chemoradiotherapy can be considered for patients with high-risk features including PLN metastases, extranodal extension, bilateral ILN involvement, and tumors in lymph nodes larger than 4 cm.

Chemoradiotherapy is a recommended strategy for patients with resistant disease. The use of chemoradiotherapy as primary treatment is a category 3 recommendation due to the limited studies that have investigated its role for treatment of penile cancer. For patients with palpable, non-bulky pN2 or pN3 disease, treatment may entail adjuvant radiotherapy, chemoradiotherapy, or chemotherapy following ILND or PLND. Chemoradiotherapy is recommended for the management of enlarged PLNs in non-surgical candidates or for local recurrence in the inguinal region or metastatic penile cancer.

NCCN Recommendations

Non-Palpable Nodes

Most low-risk patients (Tis, Ta, T1a) are followed with a surveillance protocol, as the probability of occult micrometastases in ILNs is less than 17%.^{77,105} If positive lymph nodes are found on DSNB, ILND is recommended. For patients at intermediate (T1bG1-2) or high

(T1bG3-4, T2 or greater) risk, a modified or radical inguinal lymphadenectomy is strongly recommended as occult metastatic disease ranges between 68% and 73%.^{51,77,105} If positive nodes are present on the frozen section, then a superficial and deep inguinal lymphadenectomy should be performed (with consideration of a PLND). Prophylactic EBRT (category 2B) to the ILNs should be considered in patients who are unable or unwilling to undergo surgical management. Alternatively, DSNB can be considered.

As DSNB is currently not widely practiced in the United States, this technique should be performed in tertiary care referral centers with substantial experience. DSNB is not recommended for Ta tumors, as observation alone of the ILNs is sufficient for these well-differentiated lesions in the absence of palpable adenopathy.

Unilateral Palpable Nodes <4 cm (mobile)

Percutaneous lymph node biopsy is considered standard for these patients if no risk feature is present in the primary lesion. Risk features include T1 tumors; high grade; lymphovascular invasion; and poor differentiation in more than half of the tumor cells. The NCCN Panel recommends omitting the procedure for patients with high-risk primary lesions to avoid delay of lymphadenectomy. A negative lymph node biopsy should be confirmed with an excisional biopsy. Alternatively, careful surveillance may be considered following a negative lymph node biopsy. Positive findings from either procedure warrant an immediate ILND. Additionally, in cases of pN2-3 disease, a PLND with or without adjuvant chemotherapy or chemoradiotherapy is recommended. Alternatively, chemoradiotherapy or chemotherapy alone may be given. Following treatment, all patients should enter active surveillance.



NCCN Guidelines Version 2.2017

Penile Cancer

Unilateral Palpable Nodes ≥ 4 cm (mobile)

Large, unilateral, mobile nodes should first be confirmed by percutaneous lymph node biopsy. A negative biopsy should be confirmed by an excisional biopsy. If results are negative again, the patient should be closely followed. Patients with confirmed nodes are amenable to standard or modified ILND. Neoadjuvant chemotherapy should be considered before surgery. No further treatment is necessary if no viable tumor elements are detected in the surgical specimen. Patients with viable disease in a single node after undergoing systemic chemotherapy can be considered for a PLND, but the evidence supporting this approach is sparse. If 2 or more positive nodes or extranodal extension is detected, adjuvant chemotherapy (if not already given) and/or PLND is recommended. Recent data suggest that in the setting of 4 or more positive ILNs, a bilateral PLND should be performed.¹²¹ Postoperative radiotherapy or chemoradiotherapy may be considered in patients after PLND, particularly in the setting of a positive surgical margin, viable cancer in multiple inguinal or PLNs, and/or presence of extranodal extension on the final pathologic specimen.

Unilateral Fixed Lymph Nodes or Bilateral Palpable Nodes (fixed or mobile)

In the case of large, unilateral, fixed nodes or bilateral ILNs, patients should undergo a percutaneous lymph node biopsy of the lymph nodes. A negative result should be confirmed with excisional biopsy. If results are again negative, the patient should be closely followed. Patients with a positive aspiration or biopsy should receive neoadjuvant systemic chemotherapy followed by ILND and PLND. Postoperative radiotherapy or chemoradiotherapy may be considered. As previously mentioned, in the setting of 4 or more positive ILNs, a bilateral PLND should be performed.¹²¹

Enlarged Pelvic Lymph Nodes

Patients with abnormal PLNs on imaging (CT or MRI) should proceed to a percutaneous lymph node biopsy if technically feasible. If positive, patients are stratified by resectability. Nonsurgical candidates should be treated with chemoradiotherapy. Patients with resectable disease should receive neoadjuvant systemic chemotherapy with consideration of a confirmatory percutaneous biopsy or PET/CT. Patients with disease that responds to therapy or that becomes stable should undergo bilateral superficial and deep ILND and unilateral/bilateral PLND if deemed resectable. Postoperative radiotherapy or chemoradiotherapy should be considered. Patients with disease that progresses may receive additional systemic chemotherapy with consideration of local-field radiation or participation in a clinical trial.

Surveillance

Initial treatment of the primary tumor and lymph nodes dictates the follow-up schedule (see *Surveillance Schedule* in the algorithm). A large retrospective review of 700 patients found that penile-sparing therapies carry a significantly higher risk of local recurrence (28%) than partial or total penectomy (5%) and thus require closer surveillance.¹⁰⁶ Patients without nodal involvement had a regional recurrence rate of 2% compared to 19% for patients with node-positive disease. Of all recurrences, 92% were detected within 5 years of primary treatment.

Follow-up for all patients includes a clinical exam of the penis and inguinal region. Imaging is not routinely indicated for early disease (except for obese patients or patients who have undergone inguinal surgery since a physical exam may be challenging), but may be used upon abnormal findings. For patients with N2 or N3 disease, imaging of the chest, abdomen, and pelvic area is recommended.



NCCN Guidelines Version 2.2017

Penile Cancer

Recurrence

Invasion of the corpora cavernosa is an adverse finding after initial organ-sparing treatment that warrants partial or total penectomy.^{122,123} For primary tumor recurrences without corpora cavernosa infiltration, repeat penile-sparing options can be considered (category 2B).

A recurrence in the inguinal region carries a poor prognosis (median survival, <6 months) and optimal management remains elusive. If no prior inguinal lymphadenectomy or RT was given, primary treatment for the management of ILNs can be followed. If the patient previously received lymphadenectomy or RT, subsequent-line therapies include chemotherapy followed by ILND, ILND alone, or chemoradiotherapy (if no prior RT).^{67,124} A recent study suggests that ILND may be beneficial in patients with penile cancer with locally recurrent ILN metastases.¹²⁵ While potentially curative, patients must be advised of the high incidence of postoperative complications.¹²⁵

Metastatic Disease

Imaging of the abdomen and pelvis should be obtained when metastasis is suspected to evaluate for pelvic and/or retroperitoneal lymph nodes. PLN metastasis is an ominous finding, with a 5-year survival rate of 0% to 66% for all cases and 17% to 54% for microscopic invasion only, with a mean 5-year survival of approximately 10%.^{5,126-130} In patients with ILN metastases, 20% to 30% will have PLN metastases.⁵ This can be further characterized such that if 2 to 3 ILNs are involved, there is a 23% probability of PLN involvement. With involvement of 3 or more ILNs, this probability increases to 56%.¹³¹

Lughezzani et al¹⁰⁹ identified three independent predictors of PLN metastases that included the number of inguinal metastases (odds ratio [OR], 1.92; $P < .001$), the diameter of the metastases (OR, 1.03;

$P = .001$), and extranodal extension (OR, 8.01; $P < .001$). Similar to previous studies, patients with 3 or more ILN metastases had a 4.77-fold higher risk of PLN metastasis. An ILN metastasis diameter of 30 mm or greater correlated with a 2.53-fold higher risk of PLN metastasis. Patients who showed no risk factors had a 0% risk of metastasis, suggesting that this group may not require PLND.¹⁰⁹

Pettaway et al¹³² evaluated the treatment options for stage IV penile cancer—clinical stage N3 (deep inguinal nodes or pelvic nodes) or M1 disease (distant metastases)—including chemotherapy, radiotherapy, and inguinal lymphadenectomy. Cisplatin-based regimens (paclitaxel, ifosfamide, and cisplatin or alternatively 5-FU plus cisplatin) are the most active first-line systemic chemotherapy regimens.^{33,112,133} A retrospective analysis of 30 patients with non-metastatic N2 or N3 penile cancer who received neoadjuvant cisplatin-based chemotherapy as first-line treatment demonstrated a poor response to treatment when disease progressed (median OS < 6 months).¹³⁴

Systemic chemotherapy, radiotherapy, or chemoradiotherapy may be considered for the treatment of metastatic disease. The panel did not recommend regimens containing bleomycin because of high pulmonary-related toxicity.¹³⁵ Patients with a proven objective response to systemic chemotherapy are amenable to consolidative ILND with curative potential or palliation. However, surgical consolidation should not be performed on patients with disease that progresses during systemic chemotherapy except for local symptomatic control. Preoperative radiotherapy may also be given to patients who have lymph nodes greater than or equal to 4 cm without skin fixation to improve surgical resectability and decrease local recurrence. For patients with unresectable inguinal or bone metastases, radiotherapy may provide a palliative benefit after chemotherapy. Systemic chemotherapy may also be considered upon disease progression. The



NCCN Guidelines Version 2.2017

Penile Cancer

NCCN panel strongly recommends consideration of clinical trial participation as data are limited in the second-line setting. However, in select patients, paclitaxel¹³⁶ or cetuximab¹³⁷ may be considered, especially if previous treatments did not include a similar class of agent. Best supportive care remains an option for advanced cases or cases refractory to systemic chemotherapy, radiotherapy, or chemoradiotherapy.

Summary

SCC of the penis is a disease that mandates prompt medical/surgical intervention and patient compliance to obtain the most favorable outcomes. A thorough history and physical is the initial step in this process, followed by a biopsy of the primary lesion to establish a pathologic diagnosis. Accurate clinical staging allows for a comprehensive treatment approach to be devised, thus optimizing therapeutic efficacy and minimizing treatment-related morbidity. Prognostic factors help predict if lymph node metastases are suspected in the absence of any palpable inguinal lymphadenopathy. When clinically indicated, an ILND has curative potential, particularly when performed early, with contemporary surgical series demonstrating its reduced morbidity. ≤



References

1. Pettaway CA, Lynch D, Jr, Davis D. Tumors of the Penis. In: Wein AJ, Kavoussi L, Novick AC, et al., eds. Campbell-Walsh Urology (ed 9). Philadelphia: Saunders; 2007:959-992.
2. Siegel RL, Miller KD, Jemal A. Cancer Statistics, 2017. CA Cancer J Clin 2017;67:7-30. Available at: <https://www.ncbi.nlm.nih.gov/pubmed/28055103>.
3. Curado MP, Edwards B, Shin HR, et al. eds. Cancer Incidence in Five Continents. Vol. IX. Lyon: IARC Scientific; 2007. Available at: <http://www.iarc.fr/en/publications/pdfs-online/epi/sp160/Ci5vol9.pdf>. Accessed March 10, 2017.
4. Pow-Sang MR, Ferreira U, Pow-Sang JM, et al. Epidemiology and natural history of penile cancer. Urology 2010;76:S2-6. Available at: <http://www.ncbi.nlm.nih.gov/pubmed/20691882>.
5. Horenblas S. Lymphadenectomy for squamous cell carcinoma of the penis. Part 2: the role and technique of lymph node dissection. BJU Int 2001;88:473-483. Available at: <http://www.ncbi.nlm.nih.gov/pubmed/11589660>.
6. U.S. National Library of Medicine-Key MEDLINE® Indicators. Available at: http://www.nlm.nih.gov/bsd/bsd_key.html. Accessed March 10, 2017.
7. Hernandez BY, Barnholtz-Sloan J, German RR, et al. Burden of invasive squamous cell carcinoma of the penis in the United States, 1998-2003. Cancer 2008;113:2883-2891. Available at: <http://www.ncbi.nlm.nih.gov/pubmed/18980292>.
8. Dillner J, von Krogh G, Horenblas S, Meijer CJ. Etiology of squamous cell carcinoma of the penis. Scand J Urol Nephrol Suppl 2000;189-193. Available at: <http://www.ncbi.nlm.nih.gov/pubmed/11144896>.
9. Sufrin G, Huben R. Benign and malignant lesions of the penis. In: JY G, ed. Adult and Pediatric Urology (ed 2). Chicago: Year Book Medical Publisher; 1991:1643.
10. Daling JR, Madeleine MM, Johnson LG, et al. Penile cancer: importance of circumcision, human papillomavirus and smoking in in situ and invasive disease. Int J Cancer 2005;116:606-616. Available at: <http://www.ncbi.nlm.nih.gov/pubmed/15825185>.
11. Sarkar FH, Miles BJ, Plieth DH, Crissman JD. Detection of human papillomavirus in squamous neoplasm of the penis. J Urol 1992;147:389-392. Available at: <http://www.ncbi.nlm.nih.gov/pubmed/1310122>.
12. Engels EA, Pfeiffer RM, Goedert JJ, et al. Trends in cancer risk among people with AIDS in the United States 1980-2002. AIDS 2006;20:1645-1654. Available at: <http://www.ncbi.nlm.nih.gov/pubmed/16868446>.
13. Morris BJ, Gray RH, Castellsague X, et al. The Strong Protective Effect of Circumcision against Cancer of the Penis. Adv Urol 2011;2011:812368. Available at: <https://www.ncbi.nlm.nih.gov/pubmed/21687572>.
14. Tsen HF, Morgenstern H, Mack T, Peters RK. Risk factors for penile cancer: results of a population-based case-control study in Los Angeles County (United States). Cancer Causes Control 2001;12:267-277. Available at: <https://www.ncbi.nlm.nih.gov/pubmed/11405332>.
15. Maden C, Sherman KJ, Beckmann AM, et al. History of circumcision, medical conditions, and sexual activity and risk of penile cancer. J Natl Cancer Inst 1993;85:19-24. Available at: <http://www.ncbi.nlm.nih.gov/pubmed/8380060>.
16. Depasquale I, Park AJ, Bracka A. The treatment of balanitis xerotica obliterans. BJU Int 2000;86:459-465. Available at: <http://www.ncbi.nlm.nih.gov/pubmed/10971272>.



National
Comprehensive
Cancer
Network®

NCCN Guidelines Version 2.2017

Penile Cancer

[NCCN Guidelines Index](#)
[Table of Contents](#)
[Discussion](#)

17. Micali G, Nasca MR, Innocenzi D, Schwartz RA. Penile cancer. *J Am Acad Dermatol* 2006;54:369-391. Available at: <http://www.ncbi.nlm.nih.gov/pubmed/16488287>.
18. Barbagli G, Palminteri E, Mirri F, et al. Penile carcinoma in patients with genital lichen sclerosus: a multicenter survey. *J Urol* 2006;175:1359-1363. Available at: <http://www.ncbi.nlm.nih.gov/pubmed/16515998>.
19. Stern RS. Genital tumors among men with psoriasis exposed to psoralens and ultraviolet A radiation (PUVA) and ultraviolet B radiation. The Photochemotherapy Follow-up Study. *N Engl J Med* 1990;322:1093-1097. Available at: <http://www.ncbi.nlm.nih.gov/pubmed/2320078>.
20. Pond GR, Di Lorenzo G, Necchi A, et al. Prognostic risk stratification derived from individual patient level data for men with advanced penile squamous cell carcinoma receiving first-line systemic therapy. *Urol Oncol* 2014;32:501-508. Available at: <http://www.ncbi.nlm.nih.gov/pubmed/24332646>.
21. Bleeker MCG, Heideman DAM, Snijders PJF, et al. Penile cancer: epidemiology, pathogenesis and prevention. *World J Urol* 2009;27:141-150. Available at: <http://www.ncbi.nlm.nih.gov/pubmed/18607597>.
22. Penis. In: Edge SB, Byrd DR, Compton CC, et al., eds. *AJCC Cancer Staging Manual* (ed 7). New York: Springer; 2010:447.
23. Cubilla AL, Reuter V, Velazquez E, et al. Histologic classification of penile carcinoma and its relation to outcome in 61 patients with primary resection. *Int J Surg Pathol* 2001;9:111-120. Available at: <http://www.ncbi.nlm.nih.gov/pubmed/11484498>.
24. Guimaraes GC, Cunha IW, Soares FA, et al. Penile squamous cell carcinoma clinicopathological features, nodal metastasis and outcome in 333 cases. *J Urol* 2009;182:528-534. Available at: <http://www.ncbi.nlm.nih.gov/pubmed/19524964>.
25. Ficarra V, Akduman B, Bouchot O, et al. Prognostic factors in penile cancer. *Urology* 2010;76:S66-73. Available at: <http://www.ncbi.nlm.nih.gov/pubmed/20691887>.
26. Barocas DA, Chang SS. Penile cancer: clinical presentation, diagnosis, and staging. *Urol Clin North Am* 2010;37:343-352. Available at: <http://www.ncbi.nlm.nih.gov/pubmed/20674691>.
27. Leijte JAP, Gallee M, Antonini N, Horenblas S. Evaluation of current TNM classification of penile carcinoma. *J Urol* 2008;180:933-938. Available at: <http://www.ncbi.nlm.nih.gov/pubmed/18635216>.
28. Leijte JAP, Horenblas S. Shortcomings of the current TNM classification for penile carcinoma: time for a change? *World J Urol* 2009;27:151-154. Available at: <http://www.ncbi.nlm.nih.gov/pubmed/18690458>.
29. Sobin LH, Wittekind C, International Union against Cancer. *TNM Classification of Malignant Tumours* (ed 6). New York: Wiley-Liss; 2002.
30. Slaton JW, Morgenstern N, Levy DA, et al. Tumor stage, vascular invasion and the percentage of poorly differentiated cancer: independent prognosticators for inguinal lymph node metastasis in penile squamous cancer. *J Urol* 2001;165:1138-1142. Available at: <http://www.ncbi.nlm.nih.gov/pubmed/11257655>.
31. Velazquez EF, Ayala G, Liu H, et al. Histologic grade and perineural invasion are more important than tumor thickness as predictor of nodal metastasis in penile squamous cell carcinoma invading 5 to 10 mm. *Am J Surg Pathol* 2008;32:974-979. Available at: <http://www.ncbi.nlm.nih.gov/pubmed/18460979>.
32. Pizzocaro G, Algaba F, Horenblas S, et al. EAU penile cancer guidelines 2009. *Eur Urol* 2010;57:1002-1012. Available at: <http://www.ncbi.nlm.nih.gov/pubmed/20163910>.



NCCN Guidelines Version 2.2017

Penile Cancer

33. Hakenberg OW, Comperat EM, Minhas S, et al. EAU guidelines on penile cancer: 2014 update. Eur Urol 2015;67:142-150. Available at: <http://www.ncbi.nlm.nih.gov/pubmed/25457021>.

34. Lont AP, Besnard APE, Gallee MPW, et al. A comparison of physical examination and imaging in determining the extent of primary penile carcinoma. BJU Int 2003;91:493-495. Available at: <http://www.ncbi.nlm.nih.gov/pubmed/12656901>.

35. Alnajjar HM, Lam W, Bolgeri M, et al. Treatment of carcinoma in situ of the glans penis with topical chemotherapy agents. Eur Urol 2012;62:923-928. Available at: <http://www.ncbi.nlm.nih.gov/pubmed/22421082>.

36. Lucky M, Murthy KV, Rogers B, et al. The treatment of penile carcinoma in situ (CIS) within a UK supra-regional network. BJU Int 2015;115:595-598. Available at: <http://www.ncbi.nlm.nih.gov/pubmed/25060513>.

37. Goette DK, Elgart M, DeVillez RL. Erythroplasia of Queyrat. Treatment with topically applied fluorouracil. JAMA 1975;232:934-937. Available at: <https://www.ncbi.nlm.nih.gov/pubmed/1173631>.

38. Goette DK, Carson TE. Erythroplasia of Queyrat: treatment with topical 5-fluorouracil. Cancer 1976;38:1498-1502. Available at: <http://www.ncbi.nlm.nih.gov/pubmed/991073>.

39. Mahto M, Nathan M, O'Mahony C. More than a decade on: review of the use of imiquimod in lower anogenital intraepithelial neoplasia. Int J STD AIDS 2010;21:8-16. Available at: <http://www.ncbi.nlm.nih.gov/pubmed/20029061>.

40. Deen K, Burdon-Jones D. Imiquimod in the treatment of penile intraepithelial neoplasia: An update. Australas J Dermatol 2016. Available at: <http://www.ncbi.nlm.nih.gov/pubmed/26952903>.

41. Bandieramonte G, Colecchia M, Mariani L, et al. Peniscopically controlled CO2 laser excision for conservative treatment of in situ and

T1 penile carcinoma: report on 224 patients. Eur Urol 2008;54:875-882. Available at: <http://www.ncbi.nlm.nih.gov/pubmed/18243513>.

42. Horenblas S, van Tinteren H, Delemarre JF, et al. Squamous cell carcinoma of the penis. II. Treatment of the primary tumor. J Urol 1992;147:1533-1538. Available at: <http://www.ncbi.nlm.nih.gov/pubmed/1593683>.

43. Bandieramonte G, Colecchia M, Mariani L, et al. Peniscopically controlled CO2 laser excision for conservative treatment of in situ and T1 penile carcinoma: report on 224 patients. Eur Urol 2008;54:875-882. Available at: <https://www.ncbi.nlm.nih.gov/pubmed/18243513>.

44. Colecchia M, Nicolai N, Secchi P, et al. pT1 penile squamous cell carcinoma: a clinicopathologic study of 56 cases treated by CO2 laser therapy. Anal Quant Cytol Histol 2009;31:153-160. Available at: <https://www.ncbi.nlm.nih.gov/pubmed/19639702>.

45. Meijer RP, Boon TA, van Venrooij GE, Wijburg CJ. Long-term follow-up after laser therapy for penile carcinoma. Urology 2007;69:759-762. Available at: <https://www.ncbi.nlm.nih.gov/pubmed/17445665>.

46. Parnham AS, Albersen M, Sahdev V, et al. Glansectomy and split-thickness skin graft for penile cancer. Eur Urol 2016. Available at: <https://www.ncbi.nlm.nih.gov/pubmed/27746062>.

47. O'Kane HF, Pahuja A, Ho KJ, et al. Outcome of glansectomy and skin grafting in the management of penile cancer. Adv Urol 2011;2011:240824. Available at: <http://www.ncbi.nlm.nih.gov/pubmed/21603193>.

48. Morelli G, Pagni R, Mariani C, et al. Glansectomy with split-thickness skin graft for the treatment of penile carcinoma. Int J Impot Res 2009;21:311-314. Available at: <http://www.ncbi.nlm.nih.gov/pubmed/19458620>.



49. Pietrzak P, Corbishley C, Watkin N. Organ-sparing surgery for invasive penile cancer: early follow-up data. *BJU Int* 2004;94:1253-1257. Available at: <http://www.ncbi.nlm.nih.gov/pubmed/15610100>.

50. Hatzichristou DG, Apostolidis A, Tzortzis V, et al. Glansectomy: an alternative surgical treatment for Buschke-Lowenstein tumors of the penis. *Urology* 2001;57:966-969. Available at: <http://www.ncbi.nlm.nih.gov/pubmed/11337304>.

51. Horenblas S, van Tinteren H. Squamous cell carcinoma of the penis. IV. Prognostic factors of survival: analysis of tumor, nodes and metastasis classification system. *J Urol* 1994;151:1239-1243. Available at: <http://www.ncbi.nlm.nih.gov/pubmed/8158767>.

52. Minhas S, Kayes O, Hegarty P, et al. What surgical resection margins are required to achieve oncological control in men with primary penile cancer? *BJU Int* 2005;96:1040-1043. Available at: <http://www.ncbi.nlm.nih.gov/pubmed/16225525>.

53. Bissada NK, Yakout HH, Fahmy WE, et al. Multi-institutional long-term experience with conservative surgery for invasive penile carcinoma. *J Urol* 2003;169:500-502. Available at: <http://www.ncbi.nlm.nih.gov/pubmed/12544296>.

54. Shindel AW, Mann MW, Lev RY, et al. Mohs micrographic surgery for penile cancer: management and long-term followup. *J Urol* 2007;178:1980-1985. Available at: <https://www.ncbi.nlm.nih.gov/pubmed/17869306>.

55. Choi JW, Choi M, Cho KH. A case of erythroplasia of queyrat treated with imiquimod 5% cream and excision. *Ann Dermatol* 2009;21:419-422. Available at: <http://www.ncbi.nlm.nih.gov/pubmed/20523838>.

56. Schroeder TL, Sengelmann RD. Squamous cell carcinoma in situ of the penis successfully treated with imiquimod 5% cream. *J Am Acad*

Dermatol 2002;46:545-548. Available at: <http://www.ncbi.nlm.nih.gov/pubmed/11907505>.

57. Taliaferro SJ, Cohen GF. Bowen's disease of the penis treated with topical imiquimod 5% cream. *J Drugs Dermatol* 2008;7:483-485. Available at: <http://www.ncbi.nlm.nih.gov/pubmed/18505144>.

58. Feldman AS, McDougal WS. Long-term outcome of excisional organ sparing surgery for carcinoma of the penis. *J Urol* 2011;186:1303-1307. Available at: <http://www.ncbi.nlm.nih.gov/pubmed/21862071>.

59. Frimberger D, Hungerhuber E, Zaak D, et al. Penile carcinoma. Is Nd:YAG laser therapy radical enough? *J Urol* 2002;168:2418-2421. Available at: <http://www.ncbi.nlm.nih.gov/pubmed/12441930>.

60. Azrif M, Logue JP, Swindell R, et al. External-beam radiotherapy in T1-2 N0 penile carcinoma. *Clin Oncol (R Coll Radiol)* 2006;18:320-325. Available at: <http://www.ncbi.nlm.nih.gov/pubmed/16703750>.

61. Crook J, Grimard L, Tsihlias J, et al. Interstitial brachytherapy for penile cancer: an alternative to amputation. *J Urol* 2002;167:506-511. Available at: <http://www.ncbi.nlm.nih.gov/pubmed/11792907>.

62. Rozan R, Albuissou E, Giraud B, et al. Interstitial brachytherapy for penile carcinoma: a multicentric survey (259 patients). *Radiother Oncol* 1995;36:83-93. Available at: <http://www.ncbi.nlm.nih.gov/pubmed/7501816>.

63. Zouhair A, Coucke PA, Jeanneret W, et al. Radiation therapy alone or combined surgery and radiation therapy in squamous-cell carcinoma of the penis? *Eur J Cancer* 2001;37:198-203. Available at: <http://www.ncbi.nlm.nih.gov/pubmed/11166146>.

64. Crook J, Ma C, Grimard L. Radiation therapy in the management of the primary penile tumor: an update. *World J Urol* 2009;27:189-196. Available at: <http://www.ncbi.nlm.nih.gov/pubmed/18636264>.



NCCN Guidelines Version 2.2017

Penile Cancer

65. de Crevoisier R, Slimane K, Sanfilippo N, et al. Long-term results of brachytherapy for carcinoma of the penis confined to the glans (N- or NX). *Int J Radiat Oncol Biol Phys* 2009;74:1150-1156. Available at: <http://www.ncbi.nlm.nih.gov/pubmed/19395183>.

66. Crook J, Jezioranski J, Cygler JE. Penile brachytherapy: technical aspects and postimplant issues. *Brachytherapy* 2010;9:151-158. Available at: <http://www.ncbi.nlm.nih.gov/pubmed/19854685>.

67. Heyns CF, Fleshner N, Sangar V, et al. Management of the lymph nodes in penile cancer. *Urology* 2010;76:43-57. Available at: <http://www.ncbi.nlm.nih.gov/pubmed/20691885>.

68. Solsona E, Algaba F, Horenblas S, et al. EAU Guidelines on Penile Cancer. *Eur Urol* 2004;46:1-8. Available at: <http://www.ncbi.nlm.nih.gov/pubmed/15183542>.

69. Kroon BK, Valdes Olmos RA, van Tinteren H, et al. Reproducibility of lymphoscintigraphy for lymphatic mapping in patients with penile carcinoma. *J Urol* 2005;174:2214-2217. Available at: <http://www.ncbi.nlm.nih.gov/pubmed/16280766>.

70. Hughes B, Leijte J, Shabbir M, et al. Non-invasive and minimally invasive staging of regional lymph nodes in penile cancer. *World J Urol* 2009;27:197-203. Available at: <http://www.ncbi.nlm.nih.gov/pubmed/18594830>.

71. Mueller-Lisse UG, Scher B, Scherr MK, Seitz M. Functional imaging in penile cancer: PET/computed tomography, MRI, and sentinel lymph node biopsy. *Curr Opin Urol* 2008;18:105-110. Available at: <http://www.ncbi.nlm.nih.gov/pubmed/18090498>.

72. Scher B, Seitz M, Albinger W, et al. Value of PET and PET/CT in the diagnostics of prostate and penile cancer. *Recent Results Cancer Res* 2008;170:159-179. Available at: <http://www.ncbi.nlm.nih.gov/pubmed/18019625>.

73. Scher B, Seitz M, Reiser M, et al. 18F-FDG PET/CT for staging of penile cancer. *J Nucl Med* 2005;46:1460-1465. Available at: <http://www.ncbi.nlm.nih.gov/pubmed/16157528>.

74. Tabatabaei S, Harisinghani M, McDougal WS. Regional lymph node staging using lymphotropic nanoparticle enhanced magnetic resonance imaging with ferumoxtran-10 in patients with penile cancer. *J Urol* 2005;174:923-927. Available at: <http://www.ncbi.nlm.nih.gov/pubmed/16093989>.

75. Caso JR, Rodriguez AR, Correa J, Spiess PE. Update in the management of penile cancer. *Int Braz J Urol* 2009;35:406-415. Available at: <http://www.ncbi.nlm.nih.gov/pubmed/19719855>.

76. Pizzocaro G, Piva L, Bandieramonte G, Tana S. Up-to-date management of carcinoma of the penis. *Eur Urol* 1997;32:5-15. Available at: <http://www.ncbi.nlm.nih.gov/pubmed/9266225>.

77. Solsona E, Iborra I, Rubio J, et al. Prospective validation of the association of local tumor stage and grade as a predictive factor for occult lymph node micrometastasis in patients with penile carcinoma and clinically negative inguinal lymph nodes. *J Urol* 2001;165:1506-1509. Available at: <http://www.ncbi.nlm.nih.gov/pubmed/11342906>.

78. Villavicencio H, Rubio-Briones J, Regalado R, et al. Grade, local stage and growth pattern as prognostic factors in carcinoma of the penis. *Eur Urol* 1997;32:442-447. Available at: <http://www.ncbi.nlm.nih.gov/pubmed/9412803>.

79. Li ZS, Yao K, Chen P, et al. Disease-specific survival after radical lymphadenectomy for penile cancer: prediction by lymph node count and density. *Urol Oncol* 2014;32:893-900. Available at: <http://www.ncbi.nlm.nih.gov/pubmed/24994488>.

80. Cabanas RM. An approach for the treatment of penile carcinoma. *Cancer* 1977;39:456-466. Available at: <http://www.ncbi.nlm.nih.gov/pubmed/837331>.



NCCN Guidelines Version 2.2017

Penile Cancer

81. Pettaway CA, Pisters LL, Dinney CP, et al. Sentinel lymph node dissection for penile carcinoma: the M. D. Anderson Cancer Center experience. J Urol 1995;154:1999-2003. Available at: <http://www.ncbi.nlm.nih.gov/pubmed/7500444>.

82. Leijte JAP, Kroon BK, Valdes Olmos RA, et al. Reliability and safety of current dynamic sentinel node biopsy for penile carcinoma. Eur Urol 2007;52:170-177. Available at: <http://www.ncbi.nlm.nih.gov/pubmed/17316967>.

83. Valdes Olmos RA, Tanis PJ, Hoefnagel CA, et al. Penile lymphoscintigraphy for sentinel node identification. Eur J Nucl Med 2001;28:581-585. Available at: <http://www.ncbi.nlm.nih.gov/pubmed/11383862>.

84. Gonzaga-Silva LF, Tavares JM, Freitas FC, et al. The isolated gamma probe technique for sentinel node penile carcinoma detection is unreliable. Int Braz J Urol 2007;33:58-63. Available at: <http://www.ncbi.nlm.nih.gov/pubmed/17335599>.

85. Kroon BK, Horenblas S, Meinhardt W, et al. Dynamic sentinel node biopsy in penile carcinoma: evaluation of 10 years experience. Eur Urol 2005;47:601-606. Available at: <http://www.ncbi.nlm.nih.gov/pubmed/15826750>.

86. Spiess PE, Izawa JI, Bassett R, et al. Preoperative lymphoscintigraphy and dynamic sentinel node biopsy for staging penile cancer: results with pathological correlation. J Urol 2007;177:2157-2161. Available at: <http://www.ncbi.nlm.nih.gov/pubmed/17509308>.

87. Tanis PJ, Lont AP, Meinhardt W, et al. Dynamic sentinel node biopsy for penile cancer: reliability of a staging technique. J Urol 2002;168:76-80. Available at: <http://www.ncbi.nlm.nih.gov/pubmed/12050496>.

88. Kroon BK, Horenblas S, Estourgie SH, et al. How to avoid false-negative dynamic sentinel node procedures in penile carcinoma. J

Urol 2004;171:2191-2194. Available at: <http://www.ncbi.nlm.nih.gov/pubmed/15126783>.

89. Kroon BK, Horenblas S, Deurloo EE, et al. Ultrasonography-guided fine-needle aspiration cytology before sentinel node biopsy in patients with penile carcinoma. BJU Int 2005;95:517-521. Available at: <http://www.ncbi.nlm.nih.gov/pubmed/15705071>.

90. Crawshaw JW, Hadway P, Hoffland D, et al. Sentinel lymph node biopsy using dynamic lymphoscintigraphy combined with ultrasound-guided fine needle aspiration in penile carcinoma. Br J Radiol 2009;82:41-48. Available at: <http://www.ncbi.nlm.nih.gov/pubmed/19095815>.

91. Hadway P, Smith Y, Corbishley C, et al. Evaluation of dynamic lymphoscintigraphy and sentinel lymph-node biopsy for detecting occult metastases in patients with penile squamous cell carcinoma. BJU Int 2007;100:561-565. Available at: <http://www.ncbi.nlm.nih.gov/pubmed/17578518>.

92. Djajadiningrat RS, Graafland NM, van Werkhoven E, et al. Contemporary management of regional nodes in penile cancer-improvement of survival? J Urol 2014;191:68-73. Available at:

93. Ficarra V, Galfano A. Should the dynamic sentinel node biopsy (DSNB) be considered the gold standard in the evaluation of lymph node status in patients with penile carcinoma? Eur Urol 2007;52:17-19. Available at: <http://www.ncbi.nlm.nih.gov/pubmed/17376585>.

94. Stancik I, Holtl W. Penile cancer: review of the recent literature. Curr Opin Urol 2003;13:467-472. Available at: <http://www.ncbi.nlm.nih.gov/pubmed/14560140>.

95. Kroon BK, Horenblas S, Lont AP, et al. Patients with penile carcinoma benefit from immediate resection of clinically occult lymph node metastases. J Urol 2005;173:816-819. Available at: <http://www.ncbi.nlm.nih.gov/pubmed/15711276>.



National
Comprehensive
Cancer
Network®

NCCN Guidelines Version 2.2017

Penile Cancer

[NCCN Guidelines Index](#)
[Table of Contents](#)
[Discussion](#)

96. McDougal WS. Preemptive lymphadenectomy markedly improves survival in patients with cancer of the penis who harbor occult metastases. *J Urol* 2005;173:681. Available at: <http://www.ncbi.nlm.nih.gov/pubmed/15711242>.

97. Sharp DS, Angermeier KW. Surgery of penile and urethral carcinoma. In: Wein AJ, Kavoussi L, Novick AC, et al., eds. *Campbell-Walsh Urology* (ed 9). Philadelphia: Saunders; 2007:993-1022.

98. Spiess PE, Hernandez MS, Pettaway CA. Contemporary inguinal lymph node dissection: minimizing complications. *World J Urol* 2009;27:205-212. Available at: <http://www.ncbi.nlm.nih.gov/pubmed/18762945>.

99. Catalona WJ. Re: Modified inguinal lymphadenectomy for carcinoma of the penis with preservation of saphenous veins: technique and preliminary results. *J Urol* 1988;140:836-836. Available at: <http://www.ncbi.nlm.nih.gov/pubmed/3418818>.

100. Lopes A, Rossi BM, Fonseca FP, Morini S. Unreliability of modified inguinal lymphadenectomy for clinical staging of penile carcinoma. *Cancer* 1996;77:2099-2102. Available at: <http://www.ncbi.nlm.nih.gov/pubmed/8640676>.

101. Protzel C, Alcaraz A, Horenblas S, et al. Lymphadenectomy in the surgical management of penile cancer. *Eur Urol* 2009;55:1075-1088. Available at: <http://www.ncbi.nlm.nih.gov/pubmed/19264390>.

102. Bermejo C, Busby JE, Spiess PE, et al. Neoadjuvant chemotherapy followed by aggressive surgical consolidation for metastatic penile squamous cell carcinoma. *J Urol* 2007;177:1335-1338. Available at: <http://www.ncbi.nlm.nih.gov/pubmed/17382727>.

103. Pagliaro LC, Crook J. Multimodality therapy in penile cancer: when and which treatments? *World J Urol* 2009;27:221-225. Available at: <http://www.ncbi.nlm.nih.gov/pubmed/18682961>.

104. Soria JC, Fizazi K, Piron D, et al. Squamous cell carcinoma of the penis: multivariate analysis of prognostic factors and natural history in monocentric study with a conservative policy. *Ann Oncol* 1997;8:1089-1098. Available at: <http://www.ncbi.nlm.nih.gov/pubmed/9426328>.

105. Theodorescu D, Russo P, Zhang ZF, et al. Outcomes of initial surveillance of invasive squamous cell carcinoma of the penis and negative nodes. *J Urol* 1996;155:1626-1631. Available at: <http://www.ncbi.nlm.nih.gov/pubmed/8627839>.

106. Leijte JAP, Kirrander P, Antonini N, et al. Recurrence patterns of squamous cell carcinoma of the penis: recommendations for follow-up based on a two-centre analysis of 700 patients. *Eur Urol* 2008;54:161-168. Available at: <http://www.ncbi.nlm.nih.gov/pubmed/18440124>.

107. Grabstald H. Controversies concerning lymph node dissection for cancer of the penis. *Urol Clin North Am* 1980;7:793-799. Available at: <http://www.ncbi.nlm.nih.gov/pubmed/7456188>.

108. Horenblas S, van Tinteren H, Delemarre JF, et al. Squamous cell carcinoma of the penis. III. Treatment of regional lymph nodes. *J Urol* 1993;149:492-497. Available at: <http://www.ncbi.nlm.nih.gov/pubmed/8437253>.

109. Lughezzani G, Catanzaro M, Torelli T, et al. The relationship between characteristics of inguinal lymph nodes and pelvic lymph node involvement in penile squamous cell carcinoma: a single institution experience. *J Urol* 2014;191:977-982. Available at: <http://www.ncbi.nlm.nih.gov/pubmed/24262497>.

110. Lont AP, Kroon BK, Gallee MP, et al. Pelvic lymph node dissection for penile carcinoma: extent of inguinal lymph node involvement as an indicator for pelvic lymph node involvement and survival. *J Urol* 2007;177:947-952; discussion 952. Available at: <http://www.ncbi.nlm.nih.gov/pubmed/17296384>.



National
Comprehensive
Cancer
Network®

NCCN Guidelines Version 2.2017

Penile Cancer

[NCCN Guidelines Index](#)
[Table of Contents](#)
[Discussion](#)

111. Sharma P, Djajadiningrat R, Zargar-Shoshtari K, et al. Adjuvant chemotherapy is associated with improved overall survival in pelvic node-positive penile cancer after lymph node dissection: a multi-institutional study. *Urol Oncol* 2015;33:496 e417-423. Available at: <http://www.ncbi.nlm.nih.gov/pubmed/26072110>.

112. Pagliaro LC, Williams DL, Daliani D, et al. Neoadjuvant paclitaxel, ifosfamide, and cisplatin chemotherapy for metastatic penile cancer: a phase II study. *J Clin Oncol* 2010;28:3851-3857. Available at: <http://www.ncbi.nlm.nih.gov/pubmed/20625118>.

113. Moore DH, Ali S, Koh WJ, et al. A phase II trial of radiation therapy and weekly cisplatin chemotherapy for the treatment of locally-advanced squamous cell carcinoma of the vulva: a gynecologic oncology group study. *Gynecol Oncol* 2012;124:529-533. Available at: <http://www.ncbi.nlm.nih.gov/pubmed/22079361>.

114. Bartelink H, Roelofsen F, Eschwege F, et al. Concomitant radiotherapy and chemotherapy is superior to radiotherapy alone in the treatment of locally advanced anal cancer: results of a phase III randomized trial of the European Organization for Research and Treatment of Cancer Radiotherapy and Gastrointestinal Cooperative Groups. *J Clin Oncol* 1997;15:2040-2049. Available at: <http://www.ncbi.nlm.nih.gov/pubmed/9164216>.

115. Epidermoid anal cancer: results from the UKCCCR randomised trial of radiotherapy alone versus radiotherapy, 5-fluorouracil, and mitomycin. UKCCCR Anal Cancer Trial Working Party. UK Co-ordinating Committee on Cancer Research. *Lancet* 1996;348:1049-1054. Available at: <http://www.ncbi.nlm.nih.gov/pubmed/8874455>.

116. van Doorn HC, Ansink A, Verhaar-Langereis M, Stalpers L. Neoadjuvant chemoradiation for advanced primary vulvar cancer. *Cochrane Database Syst Rev* 2006:CD003752. Available at: <http://www.ncbi.nlm.nih.gov/pubmed/16856018>.

117. Pedrick TJ, Wheeler W, Riemenschneider H. Combined modality therapy for locally advanced penile squamous cell carcinoma. *Am J Clin Oncol* 1993;16:501-505. Available at: <http://www.ncbi.nlm.nih.gov/pubmed/8256766>.

118. Eliason M, Bowen G, Bowen A, et al. Primary treatment of verrucous carcinoma of the penis with fluorouracil, cis-diamino-dichloro-platinum, and radiation therapy. *Arch Dermatol* 2009;145:950-952. Available at: <http://www.ncbi.nlm.nih.gov/pubmed/19687438>.

119. Chhabra A, Schwartz D, Leaf A, et al. Neoadjuvant concurrent chemoradiation for curative treatment of penile squamous cell carcinoma. *Case Rep Oncol Med* 2014;2014:479376. Available at: <http://www.ncbi.nlm.nih.gov/pubmed/25400960>.

120. Pond GR, Milowsky MI, Kolinsky MP, et al. Concurrent chemoradiotherapy for men with locally advanced penile squamous cell carcinoma. *Clin Genitourin Cancer* 2014;12:440-446. Available at: <http://www.ncbi.nlm.nih.gov/pubmed/24787971>.

121. Zargar-Shoshtari K, Djajadiningrat R, Sharma P, et al. Establishing criteria for bilateral pelvic lymph node dissection in the management of penile cancer: lessons learned from an international multicenter collaboration. *J Urol* 2015;194:696-701. Available at: <http://www.ncbi.nlm.nih.gov/pubmed/25801766>.

122. Chaux A, Reuter V, Lezcano C, et al. Comparison of morphologic features and outcome of resected recurrent and nonrecurrent squamous cell carcinoma of the penis: a study of 81 cases. *Am J Surg Pathol* 2009;33:1299-1306. Available at: <http://www.ncbi.nlm.nih.gov/pubmed/19471153>.

123. Ornellas AA, Nobrega BL, Wei Kin Chin E, et al. Prognostic factors in invasive squamous cell carcinoma of the penis: analysis of 196 patients treated at the Brazilian National Cancer Institute. *J Urol* 2008;180:1354-1359. Available at: <http://www.ncbi.nlm.nih.gov/pubmed/18707720>.



NCCN Guidelines Version 2.2017

Penile Cancer

124. Graafland NM, Moonen LM, van Boven HH, et al. Inguinal recurrence following therapeutic lymphadenectomy for node positive penile carcinoma: outcome and implications for management. J Urol 2011;185:888-893. Available at: <http://www.ncbi.nlm.nih.gov/pubmed/21239009>.

125. Baumgarten AS, Alhammali E, Hakky TS, et al. Salvage surgical resection for isolated locally recurrent inguinal lymph node metastasis of penile cancer: international study collaboration. J Urol 2014;192:760-764. Available at: <http://www.ncbi.nlm.nih.gov/pubmed/24603104>.

126. Lopes A, Bezerra AL, Serrano SV, Hidalgo GS. Iliac nodal metastases from carcinoma of the penis treated surgically. BJU Int 2000;86:690-693. Available at: <http://www.ncbi.nlm.nih.gov/pubmed/11069378>.

127. Pow-Sang JE, Benavente V, Pow-Sang JM, Pow-Sang M. Bilateral ilioinguinal lymph node dissection in the management of cancer of the penis. Semin Surg Oncol 1990;6:241-242. Available at: <http://www.ncbi.nlm.nih.gov/pubmed/2389105>.

128. Ravi R. Morbidity following groin dissection for penile carcinoma. Br J Urol 1993;72:941-945. Available at: <http://www.ncbi.nlm.nih.gov/pubmed/8306161>.

129. Sanchez-Ortiz RF, Pettaway CA. The role of lymphadenectomy in penile cancer. Urol Oncol 2004;22:236-244. Available at: <http://www.ncbi.nlm.nih.gov/pubmed/15271324>.

130. Srinivas V, Morse MJ, Herr HW, et al. Penile cancer: relation of extent of nodal metastasis to survival. J Urol 1987;137:880-882. Available at: <http://www.ncbi.nlm.nih.gov/pubmed/3573181>.

131. Culkin DJ, Beer TM. Advanced penile carcinoma. J Urol 2003;170:359-365. Available at: <http://www.ncbi.nlm.nih.gov/pubmed/12853775>.

132. Pettaway CA, Pagliaro L, Theodore C, Haas G. Treatment of visceral, unresectable, or bulky/unresectable regional metastases of penile cancer. Urology 2010;76:58-65. Available at: <http://www.ncbi.nlm.nih.gov/pubmed/20691886>.

133. Di Lorenzo G, Buonerba C, Federico P, et al. Cisplatin and 5-fluorouracil in inoperable, stage IV squamous cell carcinoma of the penis. BJU Int 2012;110:E661-666. Available at: <http://www.ncbi.nlm.nih.gov/pubmed/22958571>.

134. Wang J, Pettaway CA, Pagliaro LC. Treatment for metastatic penile cancer after first-line chemotherapy failure: analysis of response and survival outcomes. Urology 2015;85:1104-1110. Available at: <http://www.ncbi.nlm.nih.gov/pubmed/25819619>.

135. Haas GP, Blumenstein BA, Gagliano RG, et al. Cisplatin, methotrexate and bleomycin for the treatment of carcinoma of the penis: a Southwest Oncology Group study. J Urol 1999;161:1823-1825. Available at: <http://www.ncbi.nlm.nih.gov/pubmed/10332445>.

136. Di Lorenzo G, Federico P, Buonerba C, et al. Paclitaxel in pretreated metastatic penile cancer: final results of a phase 2 study. Eur Urol 2011;60:1280-1284. Available at: <http://www.ncbi.nlm.nih.gov/pubmed/21871710>.

137. Carthon BC, Ng CS, Pettaway CA, Pagliaro LC. Epidermal growth factor receptor-targeted therapy in locally advanced or metastatic squamous cell carcinoma of the penis. BJU Int 2014;113:871-877. Available at: <http://www.ncbi.nlm.nih.gov/pubmed/24053151>.