

Photobiomodulation: An Invaluable Tool for all Dental Specialties

Dr. Gerry Ross, Alana Ross

Although low level lasers are being used successfully in many dental clinics, the wide range of applications is still largely unknown to many practitioners, especially dental specialists. In these fields, there is the potential to see the most definitive results of what laser therapy can do to improve clinical outcomes and patient satisfaction.

Photobiomodulation (PBM), also commonly referred to as low level laser therapy (LLLT) or cold laser therapy uses light energy to elicit biological responses from the cell and normalize cell function. Numerous studies have shown that LLLT affects the mitochondria of the cell, primarily Cytochrome c-oxidase in the electron transfer chain and porphyrins on the cell membrane.^{1,2} When light photons are absorbed by these receptors in, it has been proposed that three things occur: stimulation of ATP synthesis by activation of the electron transport chain; transient stimulation of reactive oxygen species, which increases the conversion of ADP to ATP; and a temporary release of nitric oxide from its binding site on cytochrome c oxidase, which results in an increase in cell respiration (see figure 1).³

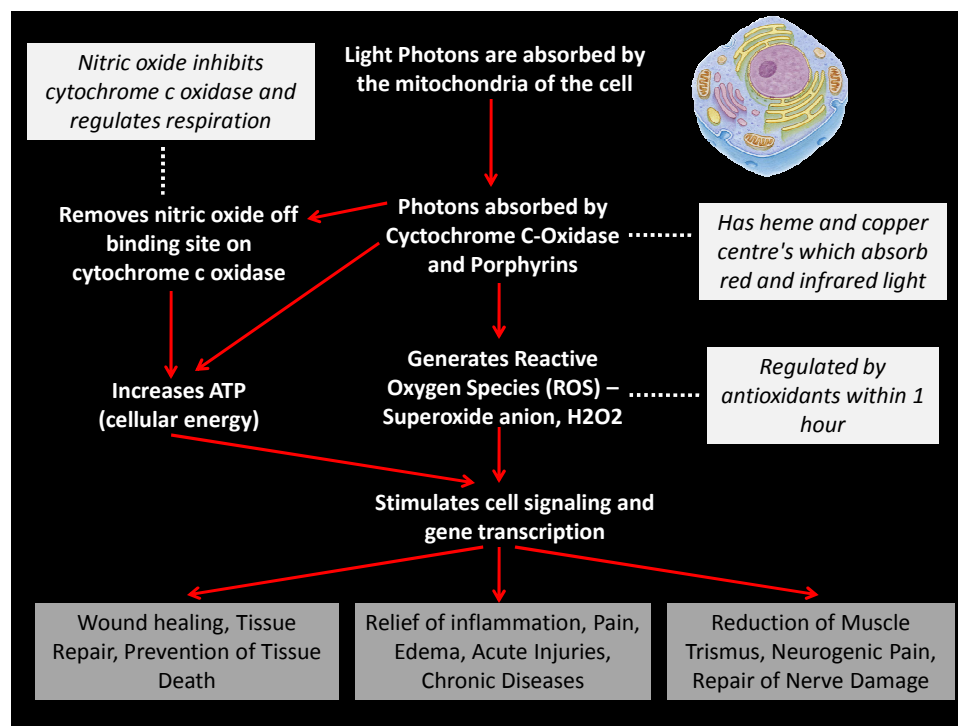


Figure 1: Summary of the Primary Mechanisms of Photobiomodulation

The clinical effects of laser therapy come not only from the direct irradiation of the tissue, but from the secondary and tertiary effects as well. Factors such as an increase in lymphatic flow and circulation; stimulation of fibroblasts, osteoblasts, odontoblasts and endorphins; reduction of the depolarization of

nerve fibres; and modulation of inflammatory chemicals all contribute to the clinical effects seen with LLLT.

From a clinical perspective, LLLT offers dental practitioners a non-invasive and non-thermal treatment modality that can be used as an adjunct to traditional therapies or as a therapeutic tool on its own.⁴ Applications such as dental analgesia, treatment of dentine hypersensitivity, healing of soft tissue lesions, reduction of pain and swelling after surgical procedures, better integration of implants into bone and faster movement of teeth during orthodontic procedures are commonly performed and thoroughly researched procedures. Patient's acceptance of laser therapy is incredibly high; the beneficial effects of laser therapy can be enhanced by the placebo effect and result in improved clinical outcomes.

Determining the Appropriate Dose

Treatment dose is probably the most important variable in laser treatment. Dose is measured in joules per square centimeter (J/cm^2) and is a measure of the amount of energy that is conducted into the tissue. Clinicians should be aware of the *optimal dose* for each application to maximize the beneficial effects of laser therapy. Clinical effects of laser, such as wound healing, pain relief or muscle relaxation, are all sensitive to different irradiances or doses. An example of this is the stimulation of fibroblasts; a dose of $5 \text{ J}/\text{cm}^2$ will stimulate the cellular activity of fibroblasts whereas higher doses inhibit cell viability and proliferation. Thus, for wound healing, you want to ideally use lower doses.⁵

The biostimulatory and inhibitory effects of lasers are governed by the *Arndt-Schultz Law*, which indicates that weak stimuli will increase physiological processes and strong stimuli will inhibit physiological activity.⁶

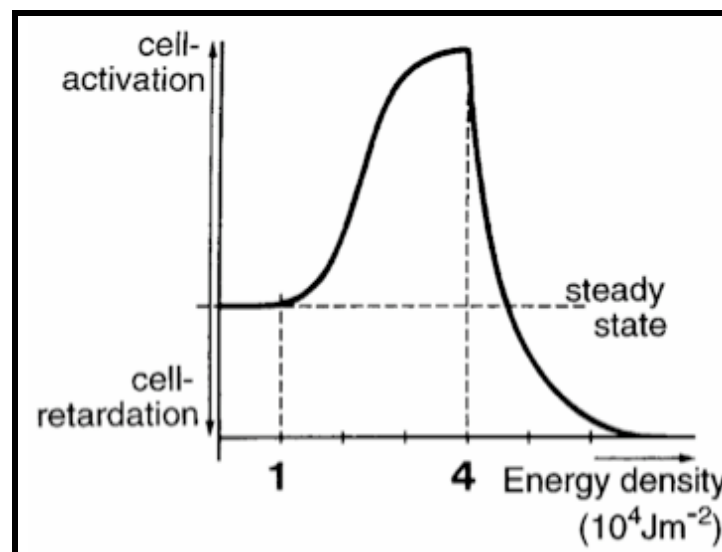


Figure 2: Arndt-Schultz Curve⁷

For applications where you are looking for biostimulation (e.g. stimulation of fibroblasts or osteoblasts for healing), you want to use a lower dose. For applications where you are looking for bioinhibition (e.g.

pain control), you want to use a higher dose. In short, there is an optimal dose for each clinical application and one should be aware of this for ideal treatment outcomes.

The importance of this parameter should always be kept in mind when using PBM; if you aren't getting the anticipated response to laser treatment, a clinician should re-evaluate the dose being used to ensure it within the optimal range. Additionally, treatments may need to be modified over time to ensure you are achieving the ideal effect from the laser dose (pain relief vs. wound healing).

Acute vs. Chronic Pain

Treatment dose and duration will largely be governed by the status of the injury. Acute pain responds the greatest to PBM and should be treated with moderate doses more frequently (often just one treatment). The reverse applies to chronic pain; treatments should be done using a lower dose over a longer period of time (e.g. treat 2-3 times per week for 3-4 weeks).

Clinical Applications in Dental Specialties

Oral Surgery

Dental surgeons can utilize LLLT in almost every facet of their practice. Any procedure a dental surgeon does, especially extraction of molars, creates an acute inflammatory response that can result in edema, bruising and pain. Currently, the primary method of dealing with the pain and discomfort of the surgical procedures are prescription of pain analgesics, many which carry side effects or decrease mental alertness. Studies have demonstrated that PBM in acute pain reduction compare well to standard NSAID treatment, with a better risk-benefit profile.⁸ In many cases, the use of PBM applied after surgery ensures that no post-op pain medications are required and patients can resume their normal day to day activities shortly after surgery.⁹ Laser therapy stimulates lymphatic flow and helps to modulate the immune response, which in turn causes significantly less swelling, bruising and pain.¹⁰ Healing is also accelerated dramatically by stimulation of fibroblasts and osteoblasts, which produces soft tissue and bone, respectively.¹¹

Post-Extraction

Following any surgical extraction, the laser is applied into the socket immediately after the surgery for reduction of pain and inflammation and then after suturing for soft tissue healing (Figure 2).

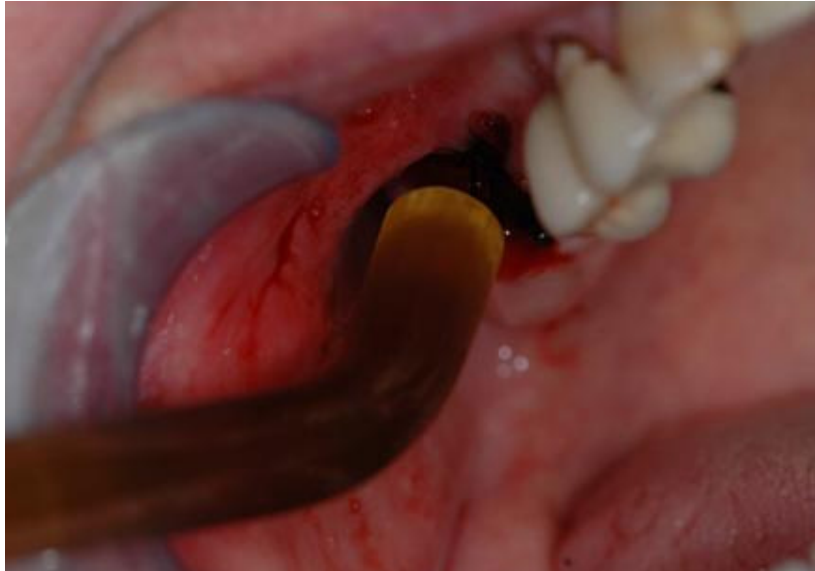

Figure 3: Application of Laser into the socket immediately following extraction

Aras and Gungormus studied the effect of PBM on trismus and facial swelling following surgical extraction of the third molar and found that both swelling and trismus were significantly less than in the placebo group on both day 2 and 7.¹² Further, in a meta-analysis of studies investigating pain within 24hr of surgery, Bjordal *et al* found that LLLT with red and infrared is effective in reducing acute inflammatory pain after molar extraction.¹³

Dry Socket

Although PBM will decrease the likelihood of a dry socket by stimulating the endothelial cells in the socket, PBM will significantly decrease the pain and stimulate healing when it does occur.

Case Study: Dry Socket

A patient had a lower 6 extracted. During the post-operative instructions, the patient (a smoker) was advised to avoid smoking cigarettes for a minimum of 2 days. Patient presented the following day with dry socket and admitted to smoking the previous evening.

Intra-oral probe was placed in socket and 48J (16J was applied repeatedly until pain relief felt by patient) of energy was applied before patient started experiencing a reduction in discomfort. A dressing was placed into socket and patient was sent home without any pain medications. Patient returned the next day for a dressing change and laser was applied into the socket using 4J between dressing change for stimulation of the epithelium in the socket. Patient did not require any additional treatments and socket healing fully.

Oral Mucositis

Oral mucositis is a debilitating and life altering condition that is a side effect of chemotherapy and radiation therapy. Oral mucositis presents as open sores over the soft tissue of the inner mouth which significantly affects a patient's quality of life and often their treatment regime. Laser therapy has been investigated as a preventative application to mucositis and as a treatment mechanism for healing erupted sores, with incredibly positive results.¹⁴ A 2006 study by Corti *et al* demonstrated that PBM accelerated the healing rate of oral mucositis by 117-164% and was able to control inflammation, maintain the mucosa integrity and improved the quality of life cancer patients¹⁵.

Case Study: Oral Mucositis

A 61 year old female patient undergoing chemotherapy for terminal cancer presented with numerous sores over the inside of her mouth. The patient could not eat, drink or swallow without extreme pain. Treatments from the oncologist (mouth rinses) had no effect on healing of the sores. Using a visible red laser (660nm), laser was applied intra-orally using 2J overlapping throughout the mouth for 2 days in a row. When the patient came in on the second day, the pain was markedly decreased and she was able to eat soup. By the fourth day, she was able to eat normally. Patient passed away in the following month but had no sores return during that time.

NOTE: Dentist contacted oncologist prior to laser treatment, who was willing to try any treatment that could work on the mucositis.

Often, oral mucositis can be so debilitating for the patient and they can't continue their cancer treatments so a tool that can treat, or prevent, the sores will have considerable clinical importance. Consultation with the oncologist should always be done prior to commencing laser treatments.

Fractures and Orthognathic Surgery

PBM accelerates healing of bone after fractures or orthognathic surgery through the stimulation of osteoblasts. A 2005 demonstrated that laser irradiation resulted in an increase in bone neoformation, with better quality bone on the irradiated groups when compared to the control group.¹⁰ Stimulation of fibroblasts and analgesia also make PBM effective in this area.

Soft Tissue Lesions

Soft tissue lesions, such as herpes lesions, denture sores, and angular cheilitis respond very well to laser irradiation. PBM decreases the pain associated with soft tissue lesions, while stimulating fibroblasts for accelerated healing. Further, it has been clinically observed that laser irradiation of herpes simplex decreases the incidence recurrence of the lesions. Schindl investigated the effect of LLLT on recurrent herpes simplex and demonstrated that 10 daily irradiations significantly lowered the incidence of local recurrence and is a beneficial treatment alternative to commonly used drugs such as acyclovir and

famciclovir.¹⁶ Marei *et al* examined the effect of laser irradiation on denture sores and noted that LLLT eased the pain caused by denture lesions while accelerating epithelization and vascularization of the lesion.¹⁷ It is advantageous to treat any soft tissue lesions as acutely as possible, especially during the prodromal stage when treating herpes lesions.

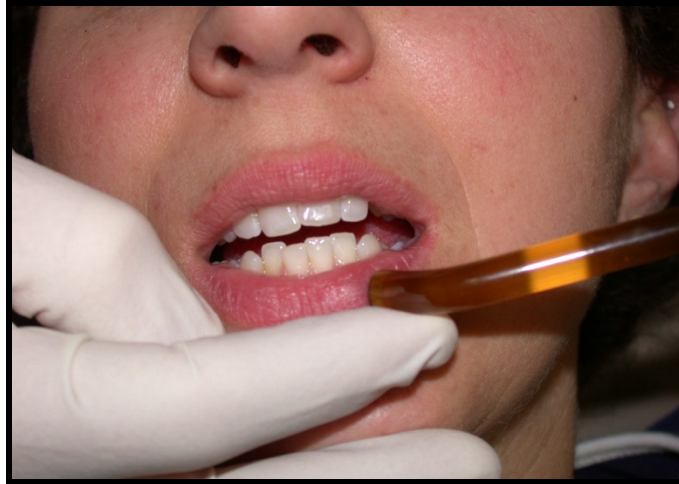

Figure 4: Treatment of Soft Tissue Lesion

Dental Infections

Laser irradiation applied to the lymph nodes and ducts will increase lymphatic flow and stimulate the immune system, bringing neutrophils to the site of infection for faster healing.

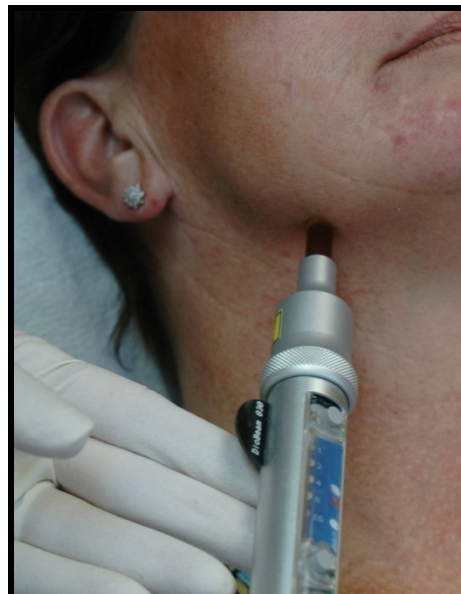

Figure 5: Application to Submandibular Lymph Nodes

It was demonstrated by Lopes *et al* that laser therapy was effective for treating acute infected processes (pericoronitis, endodontic abscess, and alveolitis). It was also shown that LLLT enhanced the lymphatic

drainage of the infected area.¹⁸ In cases where an antibiotic is given to deal with an infection, laser therapy will potentiate the uptake of the antibiotic into the system through increased circulation and lymphatic flow.

Restorative Dentistry

The effect of laser irradiation on c-fibres, endorphins levels, osteoblasts and odontoblasts make PBM an excellent tool in restorative dentistry.

Primary Tooth Restorations

There are a variety of factors that contribute to the analgesia effect produced by PBM which allows dental practitioners to perform many primary tooth restorations without anesthesia. Laser irradiation promotes a release of endorphins and serotonin; inhibits the conduction of c-fibres, the fibres that carry pulpal pain; and increases oxygenation and lymphatic drainage, which are responsible for pain relief after the first minutes of tissue irradiation.^{19, 20, 21}

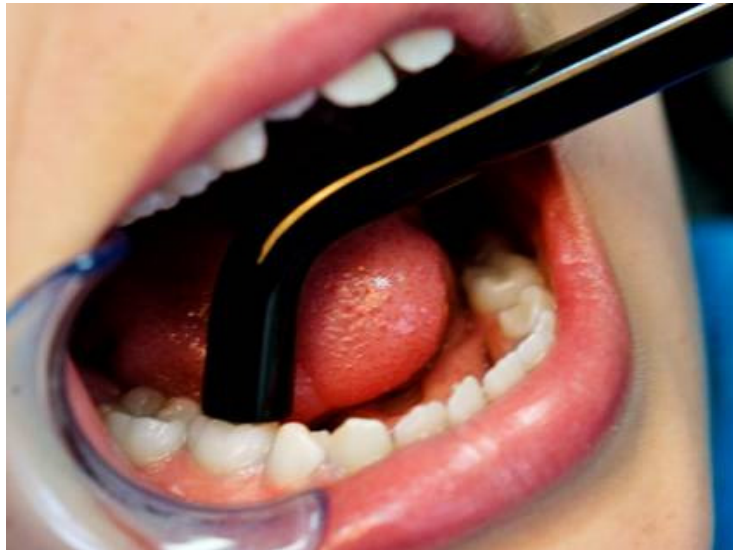

Figure 6: Promotion of Analgesia for Primary Tooth Restorations

The laser is applied over the apex of each root for analgesia and again after the tooth has been prepared for reduction of pain and inflammation. Distraction techniques are recommended to help the patient deal with the mental fears or anxiety surrounding the dental appointment. Dental analgesia doesn't seem to be as effective in permanent teeth because of the increased size of the dental pulp; however, it may still be effective for pain relief during crown cementations and decreased sensitivity during scaling appointments.

Nausea and Gagging

Application of the laser to the P6 (Pericard 6) acupuncture point on the wrist can decrease or eliminate the nausea and gagging some patients feel when taking impressions or x-rays and during dental

appointments. P6 is located on the underside of the wrist, approximately 1 inch from the distal palmar crease (approximately the width of the distal thumb phalanx).²² For patients who are extremely nauseous or anxious, application to the three acupuncture points in the wrist can be effective; H7, Lu9, and P6 are the parasympathetic calming points and are very effective in reducing anxiety.

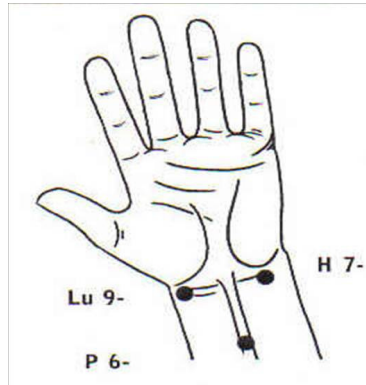


Figure 7: Parasympathetic Calming Points for Reduction of Nausea and Gagging

A 1998 report from the *British Journal of Anaesthesia* investigated the effectiveness of laser irradiation to the P6 acupuncture on postoperative vomiting. In the laser stimulation group, the incidence of vomiting was significantly lower (25%) than in the placebo group (85%), and the patients were quite receptive to the painless procedure.²³

Case Study: Nausea and Gagging

A patient presented with excessive gagging during dental appointments, especially those in which x-rays were taken. 4J was applied to P6 acupuncture point prior to dental appointment and bite wing x-rays were taken successfully without any nausea experienced by the patient.

Uptake and Elimination of Anesthesia

Laser therapy increases blood circulation and lymphatic flow which will increase the uptake and elimination of anesthesia.²⁴ Apply to the submandibular lymph nodes and the site of injection after the injection or completion of the dental appointment, for uptake and elimination, respectively.

Implant Placement

PBM can effectively decrease pain sensations during the implant placement, help speed the integration of the implant into the bone and improve the quality of the bone around the implant. A study investigating the effect on infrared light on the loading time of dental implants found a significantly greater amount of mature bone, a better distribution of bone and more organization of bone after laser irradiation, when compared to the control group.²⁵ Another study examining the effect of laser therapy

on bone demonstrated that the laser group had an abbreviated initial inflammatory response and a rapid stimulation of bone matrix formation at 15 and 45 days.²⁶

Orthodontics

Orthodontic treatments are lengthy and often painful for many patients. PBM stimulates osteoblasts which results in an increased velocity of tooth movement. It also decreases the inflammation and pain caused from the pressure on the teeth during orthodontic tooth movement.

A 2008 study investigating the effect of laser therapy on orthodontic movement showed that the velocity of canine movement was significantly higher in the laser irradiated group when compared the control group. In addition, the pain intensity was also at a lower level in the lased group throughout the entire retraction period.²⁷ Histological observations made during another orthodontic study showed that both osteoblasts and osteoclasts remained more active on the lased side which could account for the accelerated movement.²⁸ Finally, Yossef *et al* demonstrated that a single application of LLLT demonstrated a significant pain reduction at 6 and 30 hours after banding treatment.²⁹

These findings show promise for orthodontic treatments by significantly decreasing the pain associated with the treatments and increasing the velocity of tooth movement.

Periodontics

The use of PBM as a treatment modality in Periodontics is a wonderful fit, both as a treatment method on its on or as an adjunct to the increasingly popular surgical lasers. Laser irradiation stimulates fibroblasts for soft tissue healing, decreases inflammation and results in an immediate and long lasting pain relief. LLLT used in conjunction with surgical lasers for treatments such as gingivectomies, periodontitis and periodontal surgery have shown great promise in achieving improved clinical outcomes.

After Gingivectomy

Healing after a gingivectomy is often a lengthy and painful process. PBM has been shown to stimulate fibroblasts for faster regeneration of soft tissue, while providing analgesia and a modulation of the inflammatory chemicals that cause pain and discomfort. A 2006 study showed a statistically significant decrease in pocket depth at 21 and 28 days post surgery. Moreover the laser treated wounds presented with factors suggestive of better healing, including colour, contour and mucosa healing when compared with controls.³⁰ To further exemplify these positive responses, a study by Ozcelik *et al* demonstrated that LLLT enhanced epithelization and improved wound healing after gingivectomy and gingivoplasty operations.³¹

Periodontitis

Periodontitis sets in when inflammation of the gingiva damages tissue, which reduces epithelial growth and causes bone resorption. Laser therapy stimulates healing within the pocket and decreases the pain associated with periodontitis. Kreisler *et al* investigated the effect of a semiconductor laser on

periodontal pockets as an adjunct to traditional root planing and scaling and demonstrated that laser irradiated teeth had a significant decrease in tooth mobility, pocket depth and clinical attachment loss. 12% of the laser irradiated group showed an attachment gain of 3mm or more and 24% demonstrated an attachment gain of 2-3mm.³² Tooth mobility seems to be positively affected by the re-epithelization of the periodontal pockets leading to enhanced connective tissue attachment.

Periodontal Surgery

A flap incision is often used in periodontal surgery to allow for the surgical treatment of the root and bone. This surgery is often incredibly painful for the patient and creates a tender wound that can take some time to heal completely.

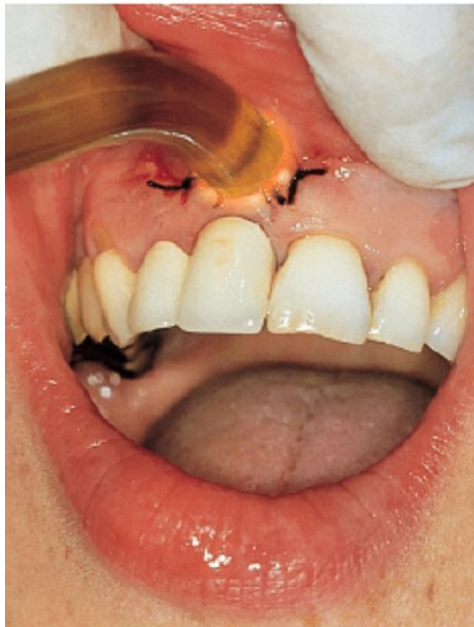

Figure 8: Laser irradiation after flap surgery

Numerous studies have demonstrated that PMB can provide significant analgesia during the healing process, shorten the course of treatment and promote soft tissue healing, making it an ideal treatment tool for periodontists. Kojovic *et al* investigated the therapeutic effects of PBM in periodontal surgery, and observed that the treated group healed in an average time of 5-10 days with an absence of pain, whereas the control group healed in 10-15 days with the presence of pain in duration to several days.³³

Endodontics

PBM is effective for reducing pain and inflammation after endodontic treatments, but can also be used as a diagnostic tool for pulp hyperemia.

Laser therapy as a Diagnostic Tool

Occasionally, a patient will present to their dental practitioner with excessive pain to a tooth that they can't accurately identify. Traditional diagnostic methods often don't show any indication of the problem, making the diagnosis and treatment stressful for both the patient and the doctor. Laser irradiation increases circulation, thus a patient will feel a sharp pain when the laser is applied to a tooth with a hyperemic pulp.³⁴ (See figure 8 for diagnostic outline)

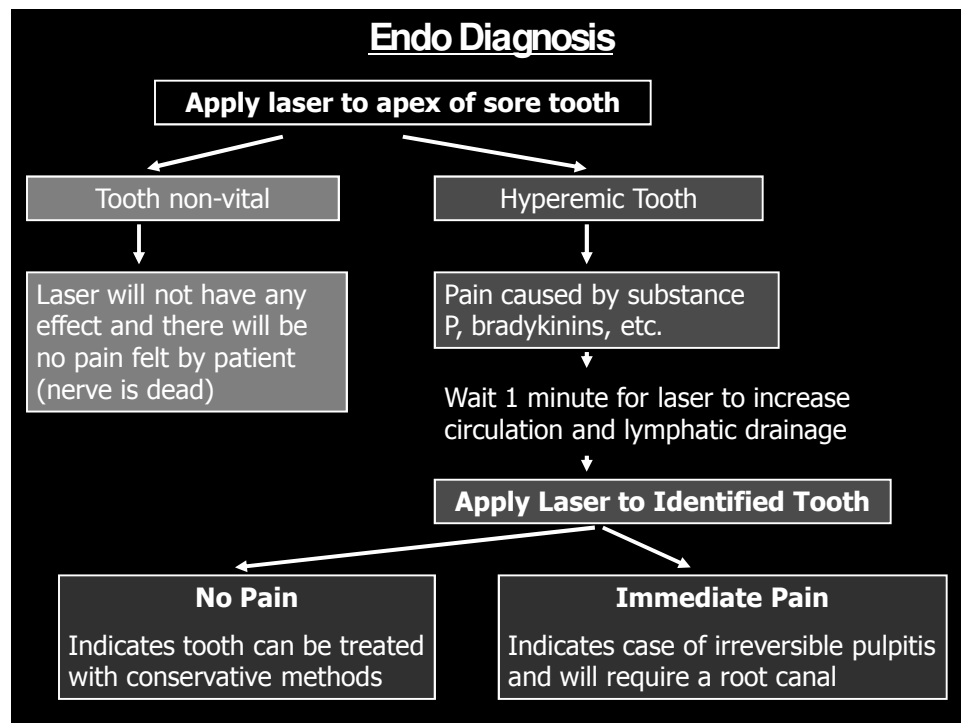


Figure 9: Flow chart for Endo Diagnosis

Dentin Hypersensitivity

Dentin Hypersensitivity is achieved by first applying the laser to get analgesia, followed by application to the dentin combined with a chemical agent for optimal desensitization. A study by Marsilo *et al* demonstrated that treatment of dentine hypersensitivity had a success rate of ~88.8% when compared to the controls, a statistically significant value. Furthermore, the statistically significant difference between the experimental and control was still evident at 60 days.³⁵

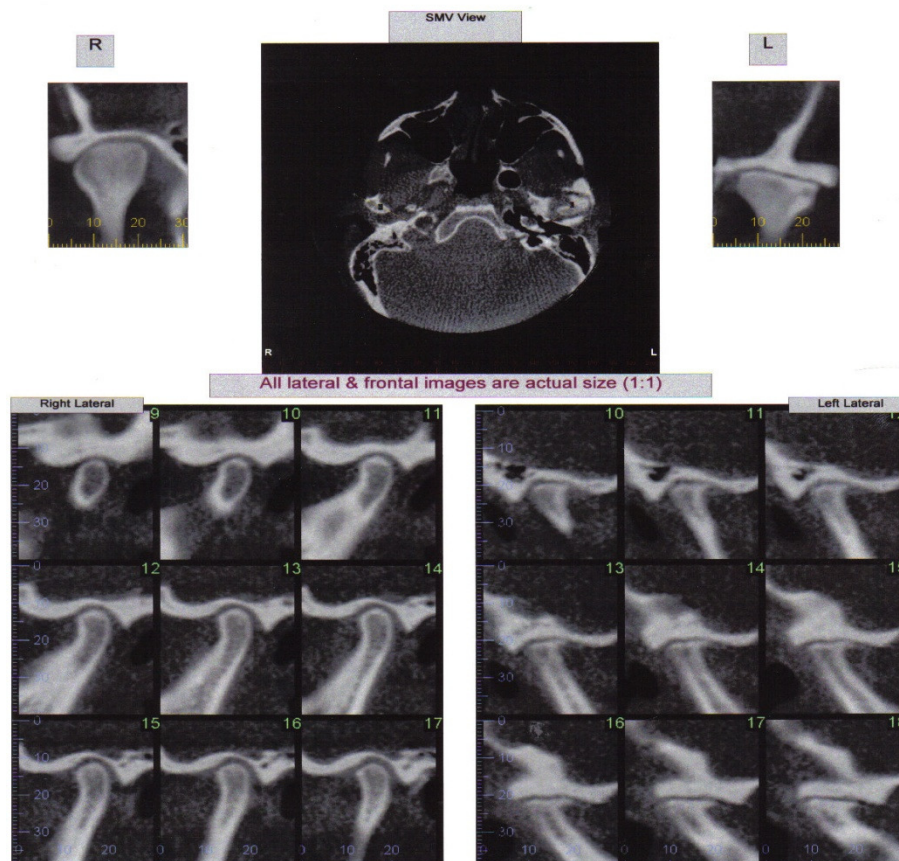
TMJ and Facial Pain

When treating TMJ or facial pain, PBM is a great tool to add to your arsenal. From simple and acute cases like facial pain after long appointments to chronic TMJ cases, laser therapy will help reduce pain and inflammation, and significantly resolve muscle trismus. In many TMJ cases, a combination of lasers and clusters of light-emitting diodes (LEDs) are the most effective for treatment. A 2007 study demonstrated that laser therapy softened overly tense and hard muscles by increasing circulation and

removing noxious deposits associated with hypertension of the tissue. The authors postulated that an increase in microcirculatory flow and volume caused muscles to relax and thus normalized the intramuscular pressure on sensory nerve endings.³⁶

Case Study: TMJ

The patient presented with pain in the left joint and a limited opening. The CT tomogram showed degenerative joint disease (osteoarthritis) of the left TMJ with no disc present.



Six applications of the laser were applied over a three week period, which treatment applications to the joint, joint capsule and the lateral pterygoid muscle. These applications resulted in the patient being pain free for the last two years.

Neuropathic Pain

Neurogenic facial pain is a debilitating condition for a patient that results in them living with excruciating pain or with a continuous dose of prescription analgesics. PBM now permits many patients to live a life free from or with less pain. A 1996 study investigating the use of PBM in the treatment of

trigeminal neuralgia found that patients who received laser treatments had a considerable reduced consumption of analgesics and should be considered as an alternative and/or supplementary treatment to traditional treatment methods.³⁷

Case Study: Neuropathic pain

Patient presented with pain in the lower left side and felt it was coming from the lower left molar. The tooth was extracted and the socket healed uneventfully but the pain got worse. At that point, there were no other problems with teeth in that quadrant, however, the pain was worsening and patient was taking Tylenol, approximately 4 times per day, every day. The laser was applied to the trigeminal nerve, the molar site, and the trigeminal ganglion. After 1 application, the patient said he was no longer taking Tylenol 3's and only took 2 Advil's at bedtime. Three days later a second application was done to the same site, and the patient reported as pain free. The pain free condition has lasted for the last three months.

Though PBM has been available to healthcare professionals since the 1960's; laser therapy didn't really begin to gain popularity until the 80's when controlled and randomized studies started being published. One common finding in the research is that there are no side effects associated with laser irradiation. In 2007, Tiina Karu reported that the effects of PBM are dependent on the initial redox status of a cell. If a cell is damaged, or in a reduced redox state, the cellular response will be stronger. Conversely, a cell which is at an optimal redox potential will have a weak or absent cellular response.² Thus, cells that are damaged or sick will respond to PBM better than cells that are healthy and functioning normally.

Photobiomodulation is an evolving technology. With every passing day, more is being discovered about the mechanisms of laser therapy, doses, treatment locations and diseases in which a laser will have an effect. At our hands is a tool that can reduce pain, stimulate wound healing, modulate the inflammatory response and regenerate nerves. Photobiomodulation can be used effectively in dental specialties to better manage treatments that are often deemed painful by patients, without prescribing pharmaceuticals that often have a number of side effects. All healthcare professions, including dentists and dental specialists, should further investigate photobiomodulation to enhance their clinical treatments and outcomes.

¹ Tafur J, Mills PJ. Low intensity light therapy: Exploring the role of redox mechanisms. *Photomedicine and Laser Surgery* 2008; 26(4): 323-328.

² Karu, T. (2008). *Low-Power Laser Therapy*. Vo-Dinh, Tuan, *Biomedical Photonics Handbook* (pp1-25). Boca Raton, Florida: CRC Press.

³ Hamblin MR, Demidove TN. Mechanisms of low level light therapy. *Proc. Of SPIE* 2006; Volume 6140: 1-11.

⁴ Lanzafame RJ, Stadler IS, Coleman J, Haerum B, Oskoui P, Wittaker M, Zhang RY. Temperature-controlled 830-nm low-level laser therapy of experimental pressure ulcers. *Photomedicine and Laser Surgery* 2004; 22(6): 483-488.

- ⁵ Hawkins D, Abrahamse H. Effect of multiple exposures of low-level laser therapy on the cellular responses of wounded human skin fibroblasts. *Photomedicine and Laser Surgery* 2006; 24(6): 705-714.
- ⁶ Sommer AP, Pinheiro ALB, Mester AR, Franke AR, Whelan HT. Biostimulatory windows in low-intensity laser activation: lasers, scanners, and NASA's light-emitting diode array system. *Journal of clinical laser medicine & surgery* 2004; 19(1): 29-33/
- ⁷ Sommer AP, Pinheiro AL, Mester AR, Franke RP, Whelan HT. Biostimulatory windows in low-intensity laser activation: lasers, scanners and NASA's light-emitting diode array system. *J Clin Laser Med Surg* 2001; 19(1): 29-33.
- ⁸ Bjordal JM, Johnson MI, Lversen V, Aimbire F, Lopes-Martins RAB. Photoradiation in acute pain: A systemic review of possible mechanisms of action and clinical effects in randomized placebo-controlled trials. *Photomedicine and Laser Surgery* 2006; 24(2): 158-168.
- ⁹ Moore KC, Hira N, Broome IJ, Cruikshank JA. The effect of infra-red diode laser irradiation on the duration and severity of postoperative pain: a double blind trial. *Laser Therapy* 1992; 4: 145-148.
- ¹⁰ Navratil L, Dylevsky I. Mechanisms of the analgesic effect of therapeutic lasers *in vivo*. *Laser Therapy* 1997; 6:33-39.
- ¹¹ Gerbi MEM, Pinheiro ALB, Marzola C, Limeira Jr FDA, Ramalho LMP, Ponzi EAC, Soares AO, Carvalho LCB, Lima HV, Goncalves TO. Assessment of bone repair associated with the use of organic bovine bone and membrane irradiated at 830nm. *Photomedicine and Laser Surgery* 2005; 23(4): 382-388.
- ¹² Aras MH, Gungormus M. The effect of low-level laser therapy on trismus and facial swelling following surgical extraction of a lower third molar. *Photomedicine and Laser Surgery* 2009; 27(1): 21-24.
- ¹³ Bjordal JM, Tuner J, Iversen VV, Frigo L, Gjerde K, Lopes-Martin RAB. A systematic review of post-operative pain relief by low level laser therapy (lllt) after third molar extraction. Abstract Congr. of the European Division of the World Federation of Laser Dentistry 2007.
- ¹⁴ Brugenera Jr A, Zanin AA, Zanin T, Bissoli C, Carvalhosa AA, Castro PHS. Prevention and treatment of oral mucositis with diode laser 660nm in patients with head and neck cancer submitted to radiotherapy and/or chemotherapy. *WALT Abstracts* 2006.
- ¹⁵ Corti L, Chiarion-Sileni V, Aversa S, Ponzoni A, D'Arcais R, Pagnutti S, Fiore D, Cotti G. Treatment of chemotherapy-induced oral mucositis with light-emitting diode. *Photomedicine and Laser Surgery* 2006; 24(2): 207-213.
- ¹⁶ Schindl A, Neumann R. Low-Intensity Laser Therapy is an Effective Treatment for Recurrent Herpes Simplex Infection. Results from a Randomized Double-Blind Placebo-Controlled Study. *Journal of Investigative Dermatology* 1999; 113: 221-223.
- ¹⁷ Marei MK, Abdel-Meguid SH, Mokhtar SA, Rizk SA. Effect of low-energy laser application in the treatment of denture-induced mucosal lesions. *J Prosthet Dent* 1997; 77(3): 256-264.
- ¹⁸ Lopes LA, Lopes A, Tuner J, Calderhead RG. The use of laser therapy in the treatment of inflammation through lymphatic drainage. *Lasers in Medical Science* 2003; 18:O208.
- ¹⁹ Hagiwara S, Iwasaka H, Hasegawa A, Noguchi T. Pre-irradiation of blood by gallium aluminum arsenide (830 nm) low-level laser enhances peripheral endogenous opioid analgesia in rats. *International Research Society* 2008; Vol 107 (3): 1058-1063
- ²⁰ Wakabayashi H, Hamba M, Matsumoto K, Tachibana H. Effect of irradiation by semiconductor laser on responses evoked in trigeminal caudal neurons by tooth pulp stimulation. *Lasers in Surgery and Medicine* 1993; 13: 605-610.
- ²¹ Pozza DH, Fregapani PW, Weber JBB, Oliveira MG, Oliveira MAM, Ribeiro-Neto N, Macedo-Sobrinho JB. Analgesic action of laser therapy (LLLT) in an animal model. *Med Oral Patol Oral Cir Bucal* 2008; 13(10): E648-652.
- ²² Kotlow, L. Lasers and pediatric dental care. *General Dentistry* 2008; 56(7): 618-627.
- ²³ Schalager A, Offer T, Baldissera I. Laser stimulation of acupuncture point P6 reduces postoperative vomiting in children undergoing strabismus surgery. *British Journal of Anaesthesia* 1998; 81: 529-532.
- ²⁴ Bjordal JM, Johnson MI, Lversen V, Aimbire F, Lopes-Martins RAB. Photoradiation in acute pain: A systemic review of possible mechanisms of action and clinical effects in randomized placebo-controlled trials. *Photomedicine and Laser Surgery* 2006; 24(2): 158-168.
- ²⁵ Lopes CB, Pinheiro ALB, Sathaiah S, Da Silva NS, Salgado MAC. Infrared laser photobiomodulation (λ 830nm) on bone tissue around dental implants: a raman spectroscopy and scanning electronic microscopy study in rabbits. *Phototherapy and Laser Surgery* 2007; 25(2): 95-101.

-
- ²⁶ Pretel H, Lizarelli RF, Ramalho LT. Effect of low-level laser therapy on bone repair: histological study in rats. *Lasers in Surgery and Medicine* 2007; 39(10): 788-796.
- ²⁷ Youssef M, Ashkar S, Hamade E, Gutknecht N, Lampert F, Mir M. The effect of low-level laser therapy during orthodontic movement: a preliminary study. *Lasers in Medical Science* 2008; 23(1): 27-33.
- ²⁸ Sun X, Zhu X, Xu C, Ye N, Zhu H. Effects of low energy laser on tooth movement and remodeling of alveolar bone in rabbits. *West China Journal of Stomatology* 2001; 19(5): 290-293.
- ²⁹ Turhani D, Scheriau M, Kapral D, Benesch T, Jonke E, Bantleon HP. Pain relief by a single low-level laser irradiation in orthodontic patients undergoing fixed appliance therapy. *Am J Orthod Dentofacial Orthop* 2006; 130(3): 371-377.
- ³⁰ Amorim JCF, De Sousa GR, Silveira, LDB, Prates RA, Pinotti M, Ribeiro MS. Clinical study of the gingiva healing after gingivectomy and low-level laser therapy 2006; 24(5): 588-594.
- ³¹ Ozcelik O, Cenk Haytac M, Kunin A, Seydaoglu G. Improved wound healing by low-level laser irradiation after gingivectomy operations: a controlled pilot study. *Journal of Clinical Periodontology* 2008; 35(3): 250-254.
- ³² Kreisler M, Haj HA, d'Hoedt B. Clinical efficacy of semiconductor laser application as an adjunct to conventional scaling and root planing. *Lasers in Surgery and Medicine* 2005; 37: 350-355.
- ³³ Kojovic DB, Pejicic A, Grigorov ID, Bojovic MD, Martinovica SR, Brankovic VZ. Therapeutic effects of low level laser therapy in periodontal surgery 2006; WALT abstracts.
- ³⁴ Kutvolgyi I. Low level laser therapy as a diagnostic tool in dentistry. *Laser Therapy* 1998; 10: 79-82,
- ³⁵ Marsilo AL, Rodrigues JR, Borges AB. Effect of the clinical application of the GaAlAs laser in the treatment of dentine hypersensitivity. *Journal of Clinical Laser Medicine and Surgery* 2003. 21(5): 291-296.
- ³⁶ Kobayshi M, Kubota J. Treatment of temporomandibular joint (TMJ) pain with diode laser therapy. *Joint International Laser Conference Abstracts* 2007: O210
- ³⁷ Eckerdal A, Bastian JL. Can low-reactive laser therapy be used in the treatment of neurogenic facial pain? A double-blind, placebo controlled investigation of patients with trigeminal neuralgia. *Laser Therapy* 1996; 8: 247-252.