

Temporomandibular Joint (TMJ) Disease

Anatomy, Diagnosis and Treatment

By Dr. Gerry Ross, DDS and Alana Ross, BScH

Introduction:

Problems of the Temporomandibular Joint (TMJ) and associated musculature are one of the most common disorders in our patients and unfortunately one of the least recognized. There are so many different philosophies espoused in the diagnosis and treatment of TMJ issues that many dentists are afraid to start treating the complex problems. However, a 90% success rate is achievable if one does a complete examination, takes a thorough history and understands the basic principles of TMJ anatomy and associated disorders. This article will outline the anatomy, differential diagnosis, history, clinical exam and lastly the treatment of the common TMJ conditions that dentists face.

For the past 60 years there has been an argument as to the role of occlusion in TMJ problems. It is my clinical opinion that occlusion does not directly cause the problem; it is when stress is added to the mix that the problems arise. When we are sitting around or talking our teeth are never in contact, they are in a rest position. When stress is added to the picture, bruxing and clenching occur along with a negative occlusal pattern. This causes undue stresses to the joint and musculature, which causes pain and dysfunction to start to occur. These forces often go beyond the adaptive ability of the orofacial complex.

Under ideal circumstances, our jaw is like a class 3 lever with the force of biting on the front teeth in Protrusive and a Cuspid protected occlusion; the joint is far away so the forces are low. Add posterior interferences and we now have a class 2 lever because the force is much closer to the joint and are much higher. Add bruxing and clenching to the mix and there is now a recipe for problems. The jaw can be thought of as a nutcracker; the joint is the hinge and the first tooth contact is the nut. Thus, the closer the first tooth contact is to the hinge, the greater the force. If the nut is at the end it is impossible to crack it but at the hinge a very small force can easily crack the nut.

Anatomy

To properly diagnose TMJ disorders and treat the problem, it is important to understand the anatomy of the joint. The Temporomandibular Joint is complex compound joint. Its structure and function can be divided into two distinct systems:

- Lower Compartment: This system is comprised of the tissues that surround the condyle and articular disc. The disc is bound to the condyle by lateral and medial discal ligaments and is responsible for the *rotational movement* of the TMJ. This is the hinge movement of a joint similar to an elbow joint
- Upper Compartment: This system is comprised of the condyle-disc complex functioning against the surface of the mandibular fossa. The disc is not attached to the fossa so *translation* can occur. This is the sliding component of the joint.

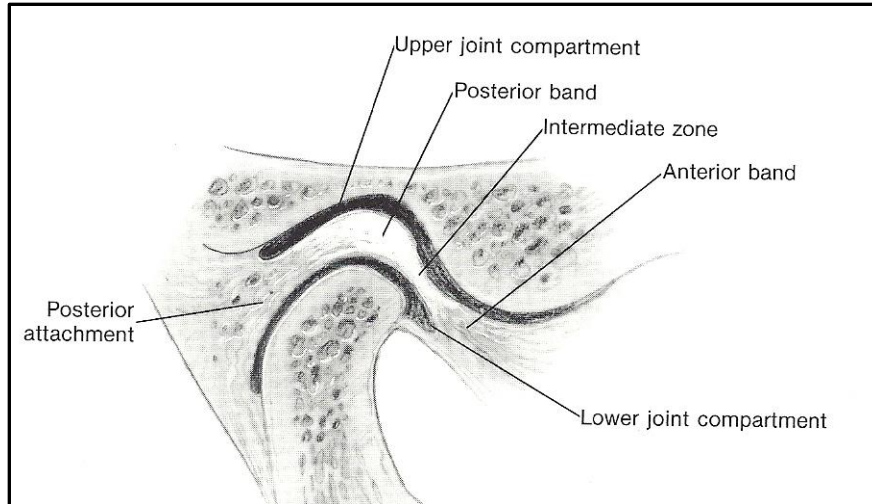


Figure 1: Temporomandibular Joint¹

The muscles surrounding and supporting the TMJ include the Temporalis, Masseter, Lateral Pterygoid, and Sternocleidomastoid. One must understand the function of each of these components to properly relate the clinical history to the examination findings.

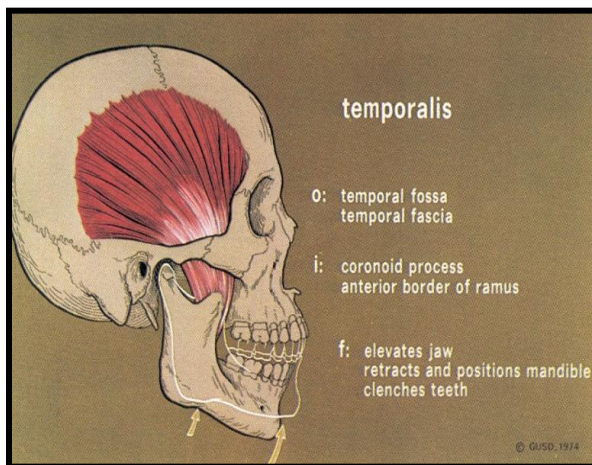


Figure 2: Temporalis Muscle

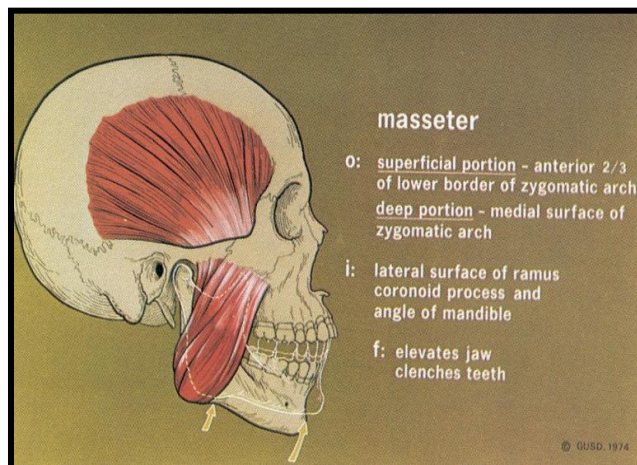


Figure 3: Masseter Muscle

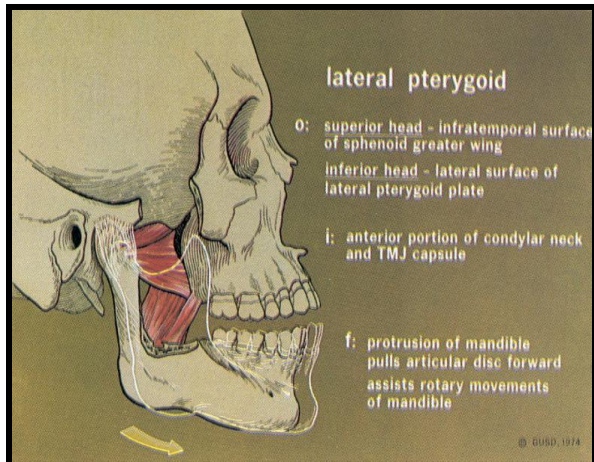


Figure 4: TMJ Capsule

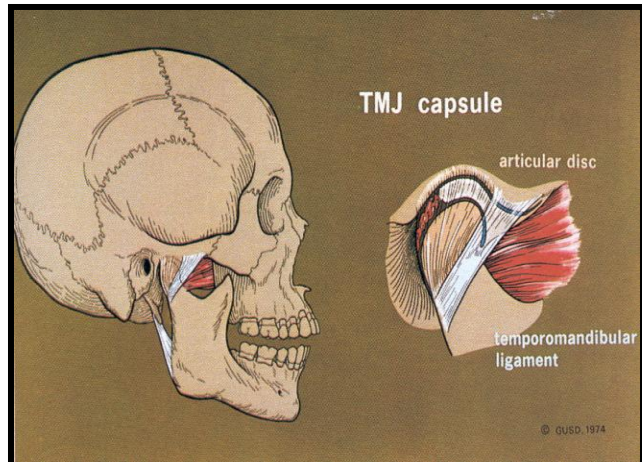


Figure 5: Lateral Pterygoid

KEYS TO TMJ TREATMENT

1. Let the Patient tell their story and LISTEN
2. History and clinical exam must correlate with clinical findings
3. To treat craniofacial pain properly, you must first know what condition you are treating
4. Always treat the source of the pain, not the site of pain
5. For successful treatment of craniofacial pain, a multi-disciplinary approach to treatment is necessary (each practitioners treatment magnifies the success when everyone works as a team)

HISTORY

The most imperative part of accurately diagnosing and effectively treating TMJ disorders is taking a thorough history, followed by an interview with the patient, clinical examination and muscle examination.

The key in obtaining all the important information is to let the patient tell their story and listen. If this is done well there will be an indication as to the nature of the problem as well the most effective treatment options in 90% of the cases. So often we are in such a hurry to tell the patient what we can do for them that we don't listen to what they are saying. Listening is probably the most important diagnostic tool that we as dentists have in our armamentarium and unfortunately the most underused one. Understanding what stresses are present in a patient's life as well as how they manage that stress is an important component of treatment

Clinical Examination

A thorough clinical exam should be taken for ALL adult patients. This allows dental practitioners establish a "normal" set-point, which can then be used as a comparison for any problems that may develop down the road. This is also valuable when dealing with insurance companies and claims. For example, there have been a number of situations in my practice where a patient has been in an auto-accident and the insurance company has tried to attribute the jaw problems to pre-existing conditions. By having all the measurements documented from the original history, the cause of the problem was

clear and the patients were able to receive proper treatment and reimbursement.

An example of the information recorded on the form is below.

OCCLUSAL FUNCTION									
Class I _____			Class II _____			Class III _____			
X-Bite(s) _____			Overbite _____			Overjet _____			
CR/CO (Leaf Gauge) _____					Slide _____				
Rt Working _____					Maximum Open _____			Opening Pattern _____	
Non-Working (bal.) _____					Vertical Dimension _____				
Left Working _____									
Non-Working (bal.) _____					Freeway Space _____				
Protrusive _____					Excessive Wear _____				
Bruxing _____			Clenching _____			Crepitus: Rt. _____		Left _____	
TMJ Right _____					TMJ Left _____				
Click: Right _____		Early _____		Middle _____		Late _____		Left _____	
		Early _____		Middle _____		Late _____			
Other _____									
X-Ray Findings _____									
Treatment Choices _____									

Figure 6: History Form - Occlusal Function

It is imperative to look for excessive wear and wear facets, as well as recession. After 40 years of practice I am confident in saying that 95% of recessions are directly associated with bruxing and especially clenching, as opposed to the normally associated culprit, brushing. Further, most Buccal grooves are abfractions from excessive force.

Muscle Examination

MUSCLE PALPATION										
	Sensitivity				Date	Sensitivity				Date
Temporalis: Ant.	Rt	SI	Mo	Sv	_____	Left	SI	Mo	Sv	_____
Mid.	Rt	SI	Mo	Sv	_____	Left	SI	Mo	Sv	_____
Post.	Rt	SI	Mo	Sv	_____	Left	SI	Mo	Sv	_____
Masseter	Rt	SI	Mo	Sv	_____	Left	SI	Mo	Sv	_____
SCM	Rt	SI	Mo	Sv	_____	Left	SI	Mo	Sv	_____
Neck Flexors	Rt	SI	Mo	Sv	_____	Left	SI	Mo	Sv	_____
Trapezius	Rt	SI	Mo	Sv	_____	Left	SI	Mo	Sv	_____
Nuchal Line	Rt	SI	Mo	Sv	_____	Left	SI	Mo	Sv	_____
Cervical Spine	Rt	SI	Mo	Sv	_____	Left	SI	Mo	Sv	_____
TMJ	Rt	SI	Mo	Sv	_____	Left	SI	Mo	Sv	_____
Styloid	Rt	SI	Mo	Sv	_____	Left	SI	Mo	Sv	_____
Digastric	Rt	SI	Mo	Sv	_____	Left	SI	Mo	Sv	_____
Medial Pterygoid	Rt	SI	Mo	Sv	_____	Left	SI	Mo	Sv	_____
Lateral Pterygoid	Rt	SI	Mo	Sv	_____	Left	SI	Mo	Sv	_____
Styloid Process	Rt	SI	Mo	Sv	_____	Left	SI	Mo	Sv	_____

Figure 7: History Form - Muscle Palpation

This brings us to the second key of Craniofacial Pain treatment: **the history and clinical findings must correlate.** If the clinical exam has findings that do not correlate with the history, the patient should be referred to a pain clinic.

Doppler Examination

A TMJ Doppler, manufactured by Great Lakes Dental Products in Buffalo, allows for the diagnosis of joint clicking, crepitus and joint inflammation. It is an ultrasound device with a microphone that allows you to hear movement within the joint.

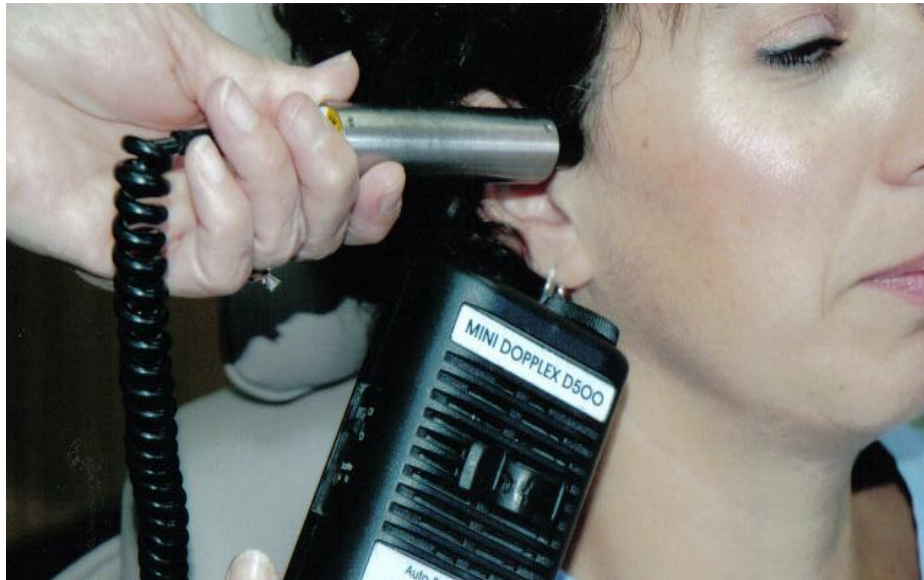

Figure 8: Doppler Examination

Disorders of the Temporomandibular Joint (TMJ) Disorders

To treat TMJ Pain properly, you must first know what condition you are treating. TMJ Disorders can be broken down into three categories:

1) Myofascial Pain

This is the most frequently seen TMJ condition and involves the muscles of the facial complex as opposed to the joint. It usually manifests as frequent headaches and sore muscles, as well as pain when chewing. This condition highlights the importance in taking a thorough history that involves questions about headaches and chewing problems. Often patients don't understand the significance of headaches or chewing problems so the condition goes unnoticed and patients suffer. Myofascial pain can affect people of all ages; however, approximately 75-80% of sufferers are female. It is also fairly common in children. Often children present with a lot of wear in their primary teeth and when asked if they suffer from headaches, 5-10% of the time the answer is affirmative and treatment is instituted.

Trigger Points are tense knots within a muscle and are often associated with myofascial pain and explain why patients often feel pain distant from the source of pain. Janet Travell mapped trigger points, which are diagramed in the book "Myofascial Pain and Dysfunction: The Trigger Point Manual".² The book is a must read for anyone treating facial pain and can save both the dentist and patient unnecessary stress when diagnosing facial pain conditions.

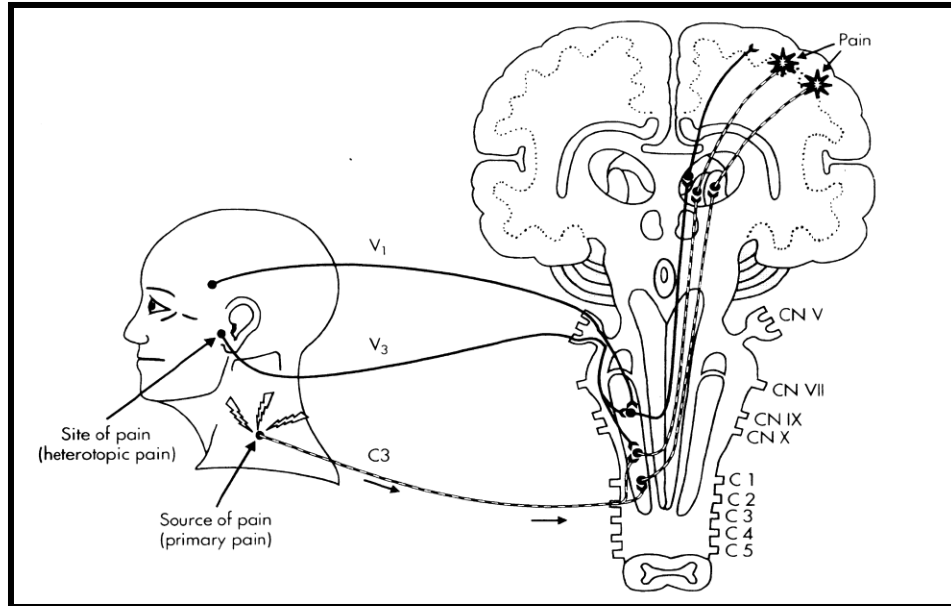


Figure 9: Trigger Points and Referred Pain³

Pain sensations from trigger points travel to the hypothalamus of the brain via ascending pathways and returns as pain via the descending pathways. It is thought the pain sensations can occasionally “jump the track” or excite a nerve pathway close by, travel down a different sensory nerve path and manifest as pain in a location different from the source. Thus, the pain is felt distant to the source of pain, making the diagnosis of myofascial pain confusing and stressful. An understanding of referred pain and a thorough muscle examination will help practitioners identify the source of the pain and appropriate treatment.

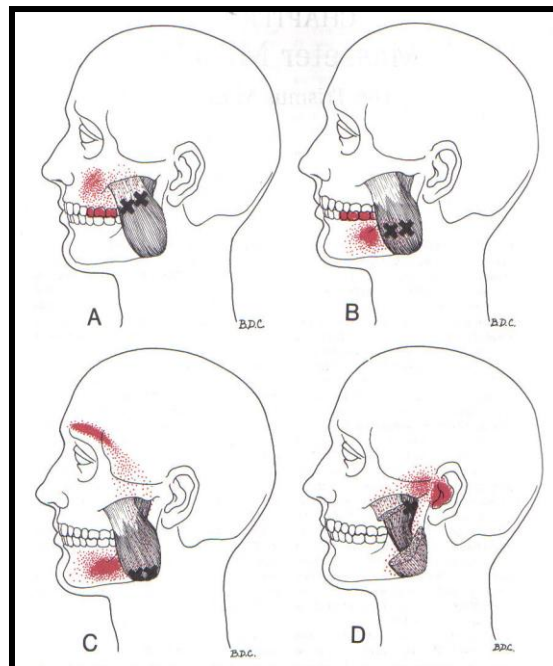


Figure 10: Referred Pain from Masseter³

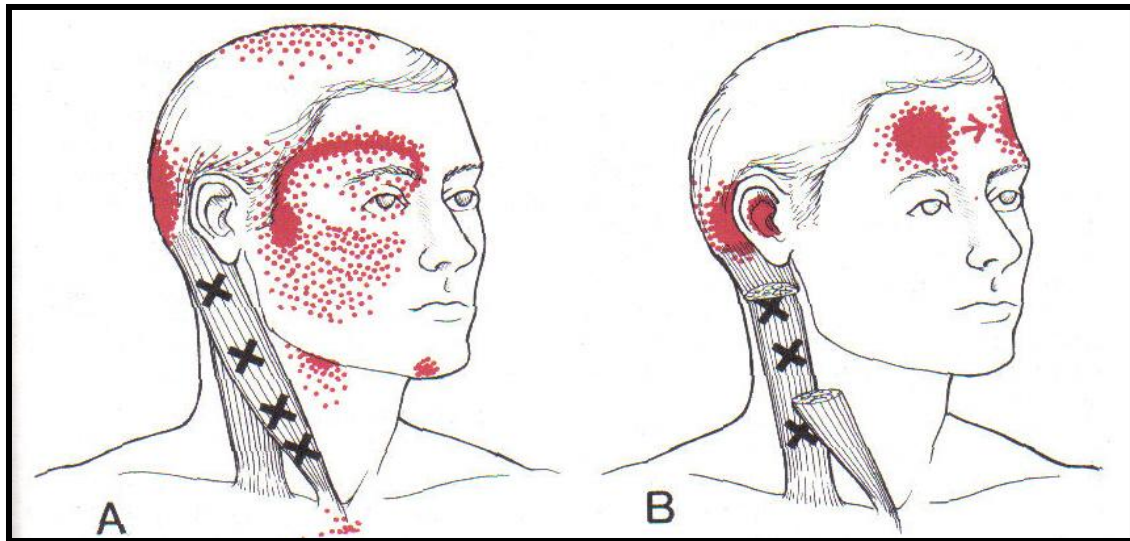


Figure 11: Referred Pain from Sternocleidomastoid Muscle³

As is seen from the diagrams above, trigger points from the masseter muscle can be felt into the ear, mandible and teeth, and from the Sternocleidomastoid Muscle in a large area around the face and head. Referred pain can make TMJ disorders confusing for many practitioners and emphasizes the fourth key to successful TMJ treatment; **always treat the source of pain, not the site of pain!** The muscle palpation examination will tell you the source of the pain.

2) Intracapsular Problems

Many patients present with clicking in their TMJ's but clinicians need to consider who should be treated? In my practice, I treat pain and limitations in function but I do not treat asymptomatic clicking. Parker Mahan did countless autopsy studies and found a high percentage of the population with disc derangements and locking; however, when he cross-referenced these findings with the patient's dental histories, there was often no evidence of pain or problems. The only time I treat clicking without pain is in a child who still has growth remaining and a functional appliance can be used. Many patients who present with locking do not have a closed lock; it is often muscular in nature. To diagnose the difference I use Stretch and Spray. A closed lock is a physical block so the opening cannot go past the end point. I cover the nose and eyes and with the mouth open I spray ethyl chloride on the masseter and temporalis muscles and then have the patient open and close 10 times before remeasuring the opening. If there is no change I consider it a closed lock but if it increases there is a muscular component and I treat it with splints and lasers.

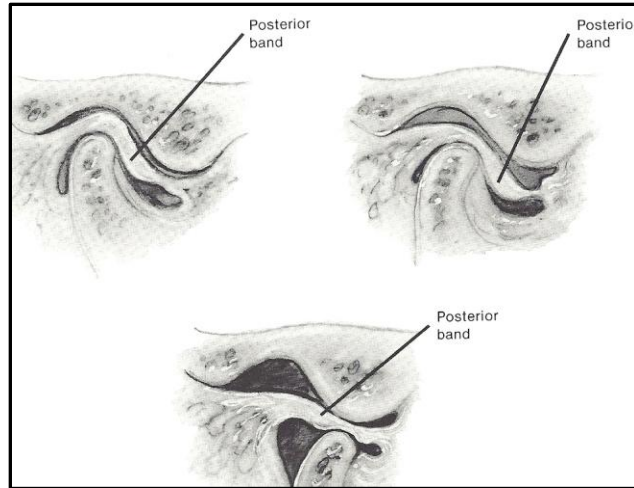


Figure 12: Open and Closed Click¹

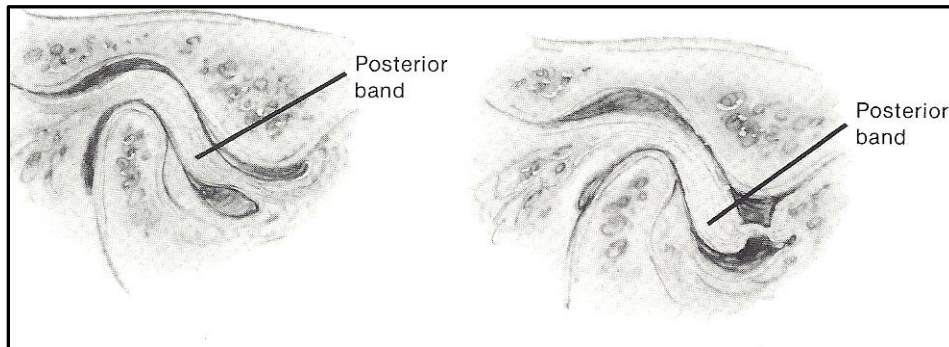


Figure 13: Closed Lock¹

3) Arthritis and Degenerative Joint Disease

- a) Osteoarthritis: This makes up 95% of the arthritic conditions encountered in TMJ disorders and is often referred to as “wear and tear arthritis”. It is often the final stage of disc deterioration where perforation of the disc occurs and the condyle rubs on the fossa and eminence during translation.

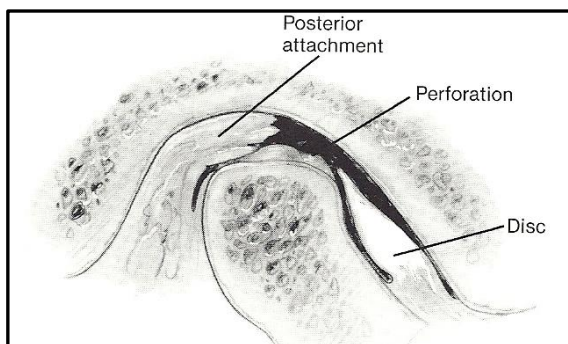


Figure 14: Perforation of the Disc¹

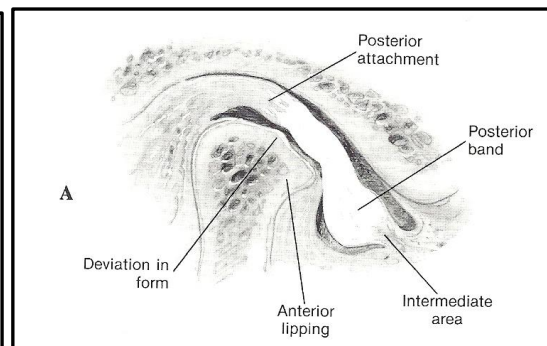


Figure 15: Internal Derangement¹

This causes bone remodeling and bone spurs. Below is a CT Tomogram from a case where this occurred.

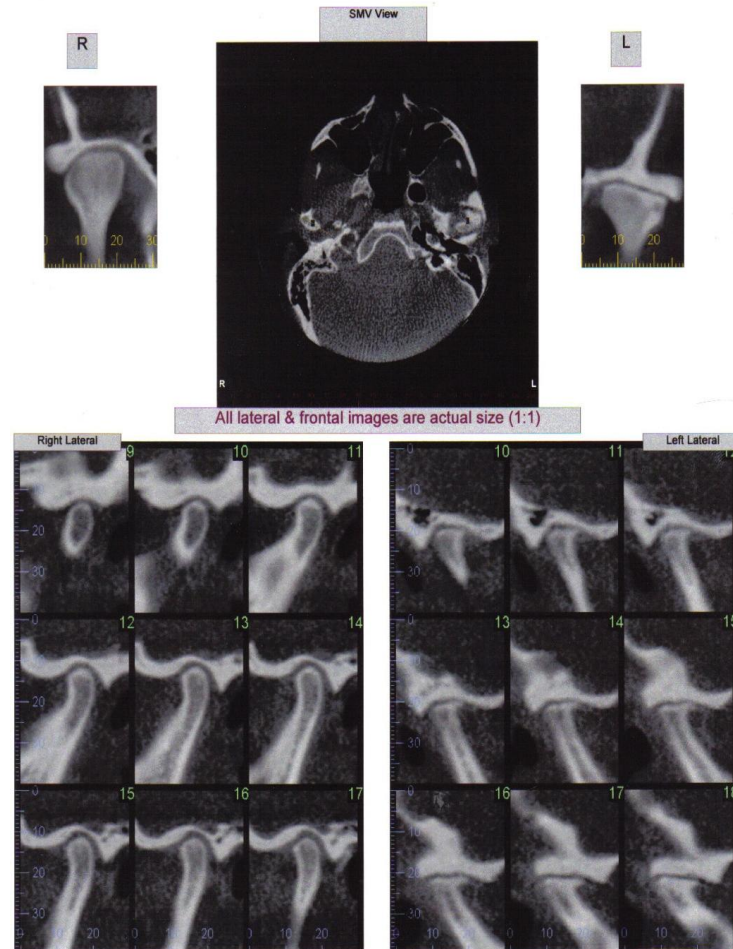


Figure 16: CT Tomogram of Arthritis

- b) Rheumatoid arthritis: This is an autoimmune condition that presents as severe inflammation of the joint followed by a period of remodeling as the body tries to heal itself and scarring occurs. It usually affects joints throughout the body and the fingers are often totally bent and disfigured.
- c) Psoriatic Arthritis: Psoriasis is also an autoimmune condition characterizes by itchy red patches and dry, white scaly areas over parts the body. In its later stage the condition can also attack the joints in the body, including the Temporomandibular Joint.

TREATMENT

Effective TMJ treatment relies on a multifaceted approach that often involves more than one

practitioner. There is not one tool that can be used to treat all cases, and practitioners need to be able to work as a team to achieve a high success rate. **Dental practitioners should work with physiotherapist, chiropractors and massage therapists to optimally treat cases of Temporomandibular Disorders.**

Within a dental practice, there are different tools that can be utilized.

Splints

There are 3 basic splints used regularly for treating TMJ disorders. In my clinical practice, my workhorse is a full coverage splint with cuspid rise and an anterior disclusion, with no posterior contacts. I use a hard-soft splint that can have some give and retention at mouth temperature so no clasps are needed. Where the teeth contact the splint I cut a trough and this is filled with hard acrylic.

In my practice I use upper and lower splints almost equally, depending on the patient's occlusal pattern and restorations. In the lower splint only, the anteriors as well as the upper lingual cusps should contact the splint. In the upper splint only, the anteriors and the lower buccal cusps contact the splint. Again in both there is a cuspid rise and an anterior disclusion.

In children, those with an active gag reflex and some emergencies I will use a NiTi appliance. This is an anterior jig that covers the upper incisors and has contacts on the lower centrals. In some emergency situations I may use a soft vinyl splint which is a hockey mouthguard made for the lower arch. It can be adjusted to a reasonable occlusion and is only worn for a few weeks. This can also be a valuable diagnostic tool when you are unsure if the patient's pain or tooth sensitivity is from the tooth or from clenching.

Low Level Laser Therapy

Low Level Laser Therapy (LLLT) uses light energy from Low Level Lasers or Superluminous Diodes (SLDs) to reduce pain, modulate the immune response and stimulate healing. There are also a number of secondary effects from LLLT, including stimulation of β -endorphins, fibroblasts for soft tissue repair and osteoblasts for the repair of bone. LLLT has been demonstrated both clinically and in research to be effective for post-surgical pain and swelling, better integration of implants, healing of soft tissue lesions, and nerve regeneration.

LLLT is an effective tool in the treatment of TMJ disorders. Studies have shown that LLLT can decrease pain, muscle trismus and swelling. There has also been some evidence to show that LLLT can help stimulate fibroblasts to form a pseudo disc in cases of disc degeneration.

In a recent study, Kobayashi *et al* hypothesized that one of the pain relief mechanisms when using LLLT in the treatment of TMJ disorders is the improved microcirculation in the temporal and masseter muscles.⁴ This improved circulation helps to remove noxious deposits associated with hypertension of the tissues. Pain relief is also felt by normalizing the intramuscular pressure on sensory nerve endings.⁵ Other studies have demonstrated that LLLT was shown to be effective for those with chronic pain and in those who did not respond to other previous conservative treatments.⁶ Further, in over 30 years of research, there have been no negative side effects associated with LLLT treatments. For more information on the use of LLLT in dentistry, refer to the Oral Health Article from December 2009.

LLLT involves the use of both Low Level Lasers and SLDs. Low level lasers are most frequently used to treat joint spaces and trigger points, whereas SLDs are often found in clusters and can be used to cover larger muscles. Although it is beneficial to use both types of devices, either can be used to effectively treat TMJ disorders.

When treating TMJ disorders, LLLT should include treatment of one or more of the following points:

- Temporomandibular Joint (opened and closed)
- Styloid Process (which includes the joint capsule)
- Lateral Pterygoid
- Trigger Points in the Sternocleidomastoid muscles
- Li4 Acupuncture Point
- Masseter Muscle Trigger Points
- Temporalis Muscle Trigger Points

It should be noted that treatment does not include all of the above points in every case; treatment locations are determined by the diagnosis and area of pain.

LLLT is most effective for acute conditions and often can be used as the sole treatment tool. In acute cases, the patient should be treated 3-4 times for one week and then left for two weeks before being reassessed. Chronic conditions often require a combination of LLLT, splints and other physical therapy. Patient should generally be treated 2-3 times per week for 3 weeks before being reassessed. It's important to note that if the patient doesn't experience any improvement the condition should be reassessed.

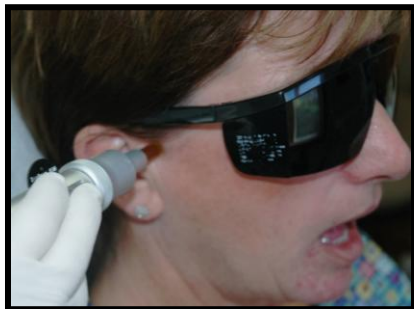


Figure 17: Styloid Process

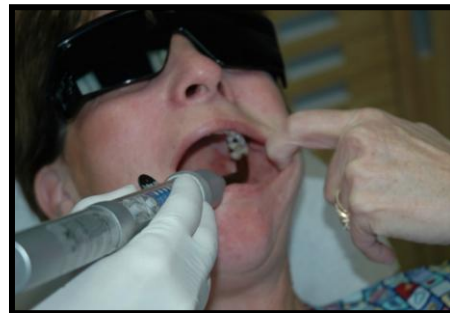

Figure 18: Lateral Pterygoid

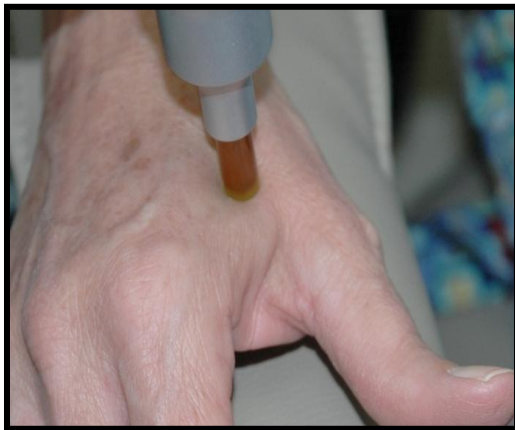

Figure 19: Li4

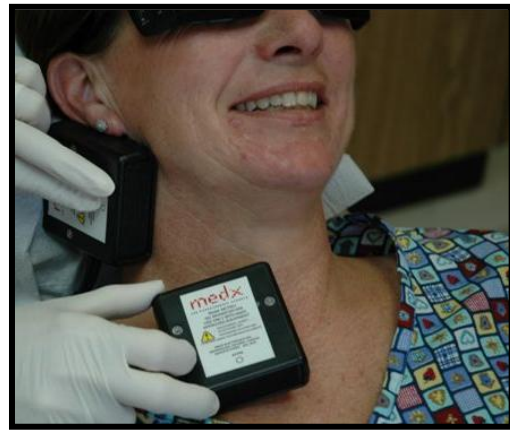

Figure 20: Sternocleidomastoid Muscle




Figure 21: Masseter Muscle

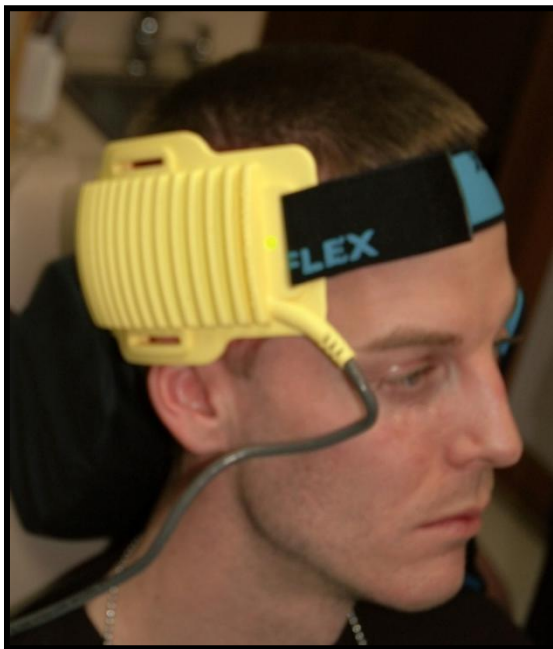

Figure 22: Temporalis Muscle

Conclusion

Many dental practitioners find TMJ disorders too complicated to treat and refer treatments to specialists. However, if a dentist understands the anatomy of the joint and takes a good history, then many cases of Temporomandibular Joint Disorders can easily be treated.

References

- ¹ Dolwick, M.F., Sanders, B. (1985). *TMJ Internal Derangement and Arthrosis: Surgical Atlas*. St. Louis: Mosby-Year Book, Inc.
- ² Travell, JG., Simons, DG. (1992) *Myofascial Pain and Dysfunction: The Trigger Point Manual (Volume 1)*. Baltimore:

³ Okeson, J.P. (1998). *Management of Temporomandibular Disorders and Occlusion: Fourth Edition*. St. Louis: Mosby-Year Book, Inc.

⁴ Kobayashi, M., Kubota, J. Treatment of Temporomandibular Joint (TMJ) Pain with Diode Laser Therapy. Department of Plastic and Reconstructive Surgery. Kyorin University School of Medicine.

⁵ Simunovic, Z. Low Level Laser Therapy with Trigger Points Technique: A Clinical Study on 243 Patients. *Journal of Clinical Laser Medicine and Surgery* 1996; 14(4): 163-167

⁶ Kubota, J, Calderhead, RG. Treatment of Temporomandibular Joint Pain with Diode Laser Therapy. *Joint International Laser Conference* 2003: O210