


A Professional Courtesy of:



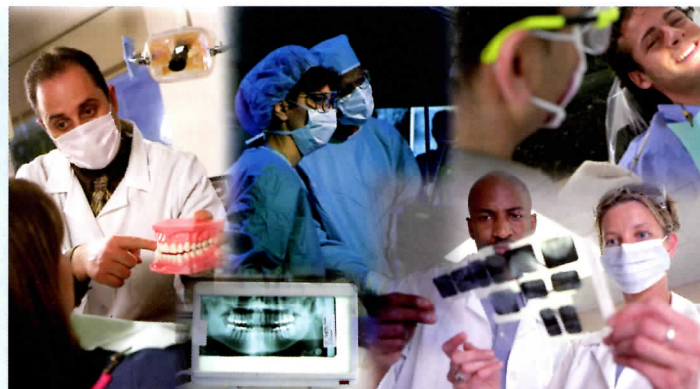## Ramin Shabtaie, D.D.S, Inc.

10921 Wilshire Boulevard, Suite 608  
Los Angeles, California 90024  
310-208-3471 • Fax: 310-208-2553  
www.ImplantsinLa.com



# Report on ORAL SURGERY™

*Focusing on Dental Implants*



## Oral Implications of Cancer Chemotherapy

**C**hemotherapy has reduced the mortality rates for individuals with cancer, but their quality of life may be diminished and their cancer therapy disrupted due to morbidity related to treatment. The goal of the dentists treating these patients is to prevent or manage oral complications. Toscano, a private practitioner from the District of Columbia, et al reviewed cancer chemotherapy, identified associated complications and recommended management of these patients.

The second leading cause of death in the United States, accounting for 1 of every 4 deaths, cancer results from numerous intrinsic and extrinsic factors, which may function synergistically or in sequence to stimulate the process of carcinogenesis. While chemotherapy, radiation therapy, hormones and immunotherapy are used to treat cancer, the most frequently employed treatment for primary tumors, particularly for well circumscribed lesions, is surgery.

Used for disseminated cancers, chemotherapy is commonly administered in conjunction with surgery and radiation treatment. Chemotherapeutic agents may also be used to diminish the size of the primary tumor before surgery. The mechanism of chemotherapeutic agents is on the action of rapidly proliferating cancer cells, but normal host cells with high mitotic activity may also be negatively affected (Table 1). Normal tissues that divide more rapidly are particularly vulnerable to injury by these agents; such tissues include the oral and gastrointestinal mucosa, the hemopoietic system and hair follicles.

### Oral complications

The effects of chemotherapy may produce a variety of oral complications, including

- mucositis
- infection
- hemorrhage
- xerostomia
- neurologic problems
- osteonecrosis
- nutritional problems

**Mucositis:** A painful and debilitating condition, mucositis involves inflammation of the mucous membrane linings of the digestive tract,

### Inside this issue

Summer 2010

- **Biofilm on Dental Implants: A Review of the Literature**
- **Peri-implant Tissue Response in the Presence of Keratinized Mucosa**
- **Relationship of Periodontal Disease and Atherosclerotic Disease**

Report on  
**ORAL SURGERY**<sup>TM</sup>  
 Summer 2010

which can result in ulceration. It is the most common oral complication associated with chemotherapeutic agents; when chemotherapy is combined with radiation therapy, mucositis occurs in 80–90% of patients. The nonkeratinized areas of the oral cavity such as the buccal mucosa, floor of the mouth, ventral surface of the tongue and the soft palate are the most frequently involved sites and are susceptible to infection from the breakdown of the mucosal barrier.

The first clinical change in the mucosa is leukoderma, a diffuse, poorly delineated area of pallor or milky-white opalescence that appears 5–10 days subsequent to the institution of chemotherapy; it resolves in 2–3 weeks in >90% of pa-

tients. Mucositis manifests as erythematous areas that break down to form ulcers covered by a yellowish white fibrin clot or pseudomembrane.

**Management** involves empirical treatment to enhance patient comfort while minimizing infections. Use of ice chips prior to and during the first 30 minutes of drug infusion reduces blood flow and mucositis. Oral care, enhanced by mouthrinses without alcohol, phenol, aromatics, astringents, oils or antiseptics, removes debris. A sodium bicarbonate rinse and topical anesthetics such as viscous lidocaine have also been effective.

**Infection:** Infections of the oral cavity account for 25–50% of infections in chemotherapy patients and may involve the teeth, gingiva, salivary glands or mucosa. If the patient's granulocyte count drops to <1000 mm<sup>3</sup>, pathogenic bacteria found subgingivally or in the periradicular region may acutely exacerbate preexisting periodontal or periradicular infections. A white blood cell count <2500/mm<sup>3</sup> or an absolute neutrophil count <500/mm<sup>3</sup> requires antibiotic prophylaxis prior to any

dental treatment likely to produce bleeding or bacteremia.

**Management** may include the use of fluconazole, the most common and frequently used prophylactic agent to prevent oropharyngeal candidiasis in the myelosuppressed patient. Chemotherapy may also allow the emergence of viral infections such as herpes simplex, varicella zoster and cytomegalovirus, for which the use of acyclovir may be indicated.

**Hemorrhage:** Hemorrhages may be produced secondarily by the chemotherapeutic agents' proclivity to cause thrombocytopenia.

**Management** involves eliminating sharp restorations, fractured teeth, orthodontic brackets and preexisting oral disease before chemotherapy to avoid hemorrhage. If platelet counts are >50,000/mm<sup>3</sup>, dental treatment usually may proceed.

**Xerostomia:** Dry mouth may result from certain chemotherapeutic agents. Normal salivary flow frequently returns several months after completion of the chemotherapy.

**Management** may include the use of ice chips, gum containing xylitol, carboxymethylcellulose-based saliva substitutes or parasympathomimetic drugs such as pilocarpine.

**Neurologic problems:** These can take the form of pain or paresthesia from chemotherapy-induced neuropathy.

**Management** should be limited; neurologic symptoms frequently resolve after the chemotherapeutic agent is stopped.

**Bisphosphonate-induced osteonecrosis:** Associated with pamidronate and zoledronate, which deplete the osteoclast population and suppress bone turnover, osteonecrosis of the jaw is expressed clinically as exposed nonhealing bone. Discontinuing intravenous bisphosphonates does not appear to reduce the incidence of osteonecrosis.

**Table 1. Class of chemotherapeutic agents, mechanisms of action and examples of available agents**

Class of chemotherapeutic agent	Mechanisms of action	Examples of available agents
Alkylating agents	DNA alkylation	Mechlorethamine, chlorambucil
Antimetabolites	Replace natural building blocks in DNA molecules	6-mercaptopurine, 5-fluorouracil, methotrexate
Antitumor antibiotics	Bind with DNA, preventing RNA synthesis	Doxorubicin, mitoxantrone, bleomycin
Steroidal and hormonal agents	Alter hormonally dependent intracellular environment of cancer cells	Tamoxifen
Plant alkaloids	Block cell division during mitosis	Vincristine, vinblastine
Bisphosphonates	Inhibit osteoclastic activity	Ibandronate, zoledronate, alendronate
Nitrosoureas	Inhibit changes necessary for DNA repair	Carmustine, lomustine

**Management** should begin prior to or within the first 3 months of bisphosphonate administration. Unrestorable teeth should be removed, followed by required periodontal surgery and maintenance. After 5 doses of intravenous bisphosphonate, all surgical procedures in the jaw should be avoided if possible.

**Nutritional problems:** Chemotherapy-induced mucositis could reduce the patient's nutritional and caloric intake.

**Management** may involve a liquid diet.

### Conclusion

Acute and chronic oral complications may be experienced by patients treated with chemotherapeutic agents. The dentist must be aware of the various complications and their prevention and management.

*Toscano N, Holtzclaw D, Hargitai IA, et al. Oral implications of cancer chemotherapy. J Implant Adv Clin Dent 2009;1:51-67.*

## Biofilm on Dental Implants: A Review of the Literature

**I**n a literature review, Subramani et al from the University of Zurich, Switzerland, sought to identify factors that may contribute to the formation of biofilm on dental implants. The search focused on implant surface features and chemistry, and the design characteristics of the abutment complex.

Composed of microbial complexes embedded in a matrix of polymers, mostly of bacterial and salivary origins, biofilms on dental implants are the principal source of peri-implantitis and dental implant failure. The transmucosal healing following attachment of the implant abutment creates the adsorption of the sali-

vary pellicle; the accumulation of bacteria and biofilm that follows induces an inflammatory response.

The process of microbial colonization on dental implants and the formation of biofilm on teeth and dental implants are similar. Typically, anaerobes increase at 48 hours, while streptococci and *Actinomyces* species predominate after 4 hours and establish a favorable environment for late colonizers, such as

- *Porphyromonas* species
- *Prevotella* species
- *Capnocytophaga* species
- *Fusobacterium* species

Rough titanium surfaces produce the highest degree of bacterial attachment. Hydrophobic (low affinity for water) and rough surfaces demonstrate more bacterial colonization.

Implant and abutment biomaterial design features collectively contribute to biofilm formation along the implant-transmucosal abutment interfaces, transmucosal abutment-prosthesis interfaces, implant-prosthesis interfaces and on the surfaces of the implant, abutment and the prosthesis. Microscopic gaps between interfaces, exposure of plasma-sprayed coatings and threaded surfaces of the implants, and overcontouring of the implant restoration contribute to an environment conducive to biofilm formation.

### Conclusion

The authors concluded that increases in surface roughness, surface-free energy, surface chemistry and design characteristics of the implant-abutment complex collectively influence biofilm formation on dental implants that can lead to implant failure.

*Subramani K, Jung RE, Molenberg A, Hämmerle CHF. Biofilm on dental implants: a review of the literature. Int J Oral Maxillofac Implants 2009;24:616-626.*

## Peri-implant Tissue Response in The Presence of Keratinized Mucosa

**T**o evaluate peri-implant tissue response in the presence of keratinized mucosa, Kim et al from Seoul National University Bundang Hospital, South Korea, studied 276 implants placed in 100 patients, with an average follow-up of 13 months. They measured the width of the keratinized mucosa and compared and evaluated the measurements using the gingival inflammation index (GI), plaque index (PI), the pocket depth (PD), mucosal recession and marginal bone resorption.

To maintain healthy gingival tissues, the width of keratinized mucosa, which consists of free gingival tissue and nonmobile attached gingival tissue, should be >2 mm. The keratinized gingiva retards the movement of the mucosa in the region of the cover screw exposed by external force.

The patients were divided into 2 groups: those with sufficient keratinized mucosa ( $\geq 2$  mm) and those with insufficient keratinized mucosa (<2 mm). The GI, PI and PD did not demonstrate statistically significant differences between groups with sufficient and insufficient keratinized mucosa, but mucosal recession and marginal bone resorption did show statistically significant increases in the group with insufficient keratinized mucosa.

The mean width of the insufficient keratinized mucosa group was widest in the maxillary premolar region (0.90 mm) and narrowest in the maxillary molar region (0.38 mm); overall, the mean width at all sites was 0.56 mm. In contrast, the mean width of the sufficient keratinized

Report on  
**ORAL SURGERY™**  
 Summer 2010

mucosa group (3.17 mm) was widest in the maxillary premolar region (3.78 mm) and narrowest in the mandibular molar region (2.77 mm); overall, the mean width at all sites was 3.17 mm.

**Conclusion**

Insufficient keratinized mucosa in the region of implant placement did not seem to compromise oral hygiene management or soft-tissue health. However, the deficiency of keratinized mucosa increased the risk of gingival recession and marginal bone resorption. The implication appears to be that, in cases requiring long-term maintenance and esthetically pleasing appearance, the existence of an appropriate quantity of keratinized mucosa is required.

*Kim B-S, Kim Y-K, Yun P-Y, et al. Evaluation of peri-implant tissue response according to the presence of keratinized mucosa. Oral Surg Oral Med Oral Pathol Oral Radiol Endod 2009;107:e24-e28.*

**Relationship of Periodontal Disease and Atherosclerotic Disease**

**J**oshipura et al from the Harvard School of Dental Medicine, Massachusetts, reviewed the evidence regarding the relationship between periodontal disease and atherosclerotic disease, including ischemic heart disease, peripheral

arterial disease and ischemic stroke (Figure 1). The authors examined whether a causal link could be established between periodontal disease and atherosclerotic disease or whether the relationship is due to common risk factors (Figure 2). The authors applied established causal inference criteria to evaluate the evidence in the existing literature.

Inflammation is a factor in the pathogenesis of atherosclerosis, whereby inflammatory cells and cytokines contribute to the formation of plaque within the blood vessels; maintenance and rupture of the plaque create the thrombotic events. There is evidence that chronic infection may initiate atherosclerosis and/or interact with additional risk factors that amplify the inflammatory response within the blood vessel.

Smoking, diabetes mellitus and obesity can trigger inflammation, have been associated with periodontal disease and cardiovascular disease, and could explain the apparent association even if no causal relationship exists. The authors found that the magnitude and consistency of the association between periodontal disease and atherosclerotic disease was strong for ischemic stroke and low for ischemic heart disease. However, a biologic plausibility exists for all the established relationships between periodontal disease and atherosclerotic disease.

**Conclusion**

The authors concluded that the evidence is insufficient to prove a causal relationship between periodontal disease and atherosclerotic disease. However, suggestive evidence exists, with the strongest for

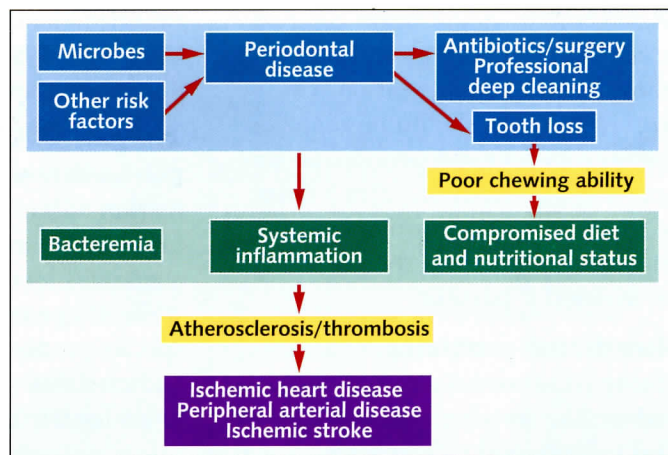


Figure 1. Potential biologic pathways relating oral and atherosclerotic diseases.

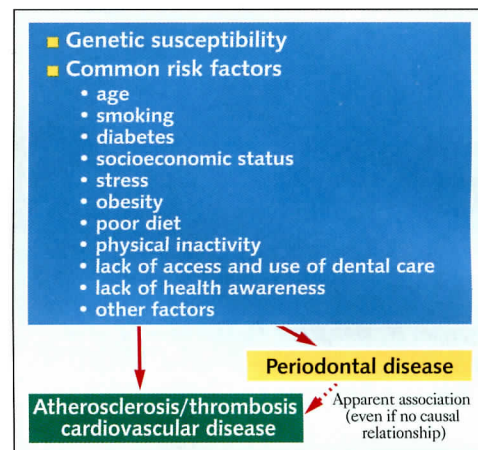


Figure 2. Common risk factors.

a relationship between periodontal disease and stroke.

*Joshipura K, Zavallos JC, Ritchie CS. Strength of evidence relating periodontal disease and atherosclerotic disease. Compend Contin Educ Dent 2009;30:430-439.*

**In the next issue**

- Systemic conditions and treatments as risks for implant therapy
- Local risk factors for implant therapy
- Diabetes mellitus: Considerations in dentistry

*Do you or your staff have any questions or comments about Report on Oral Surgery?*

*Please call or write our office. We would be happy to hear from you.*